Oecologia Australis (ISSN: 2177-6199)
Ahead of print (https://revistas.ufrj.br/index.php/oa/issue/view/1109/showToc)
Article ID: AO#73365
Published online: 07 NOVEMBER 2026

ChHV5 circulation in juvenile Chelonia mydas

FIBROPAPILLOMATOSIS AND CHHV5 CIRCULATION IN JUVENILE GREEN TURTLES FROM COASTAL DEVELOPMENTAL HABITATS IN BRAZIL

Isabel Rangel Prado Ferreira [1,2], Larissa Pereira Rodrigues [1,2], Pedro Paulo de Oliveira Nogueira [1,2], Yohany Arnold Alfonso Pérez[3], Camila Miguel[4], Gustavo Martinez Souza[5], Rodrigo Hidalgo Friciello Teixeira [2, 6] & Lígia Souza Lima Silveira da Mota [1,2] *

1 São Paulo State University, Institute of Biosciences, Department of Genetics, Microbiology and Immunology, Botucatu, São Paulo, Brazil

2 São Paulo State University, School of Veterinary Medicine and Animal Science, Graduate Program in Wild Animals, Botucatu, São Paulo, Brazil

3 Fluminense Federal University, Faculty of Veterinary Medicine, Postgraduate Program in Veterinary Medicine, Niterói, Rio de Janeiro, Brazil

4 Instituto Marcos Daniel, Vitória, Espírito Santo, Brazil

5 Federal University of Rio Grande, Institute of Mathematics, Statistics and Physics, Laboratory of Environmental Statistics, Rio Grande, Rio Grande do Sul, Brazil

6 Municipal Zoological Park Quinzinho de Barros, Sorocaba, São Paulo, Brazil

E-mails: isabel.rp.ferreira@unesp.br; pereira.rodrigues@unesp.br; oliveira.nogueira@unesp.br; yohanyperez@id.uff.br; camila.miguel@edu.pucrs.br; gustavomarsouza@gmail.com; rhftzoo@hotmail.com; ligia.mota@unesp.br

(*corresponding author)

Abstract: Fibropapillomatosis (FP) is a tumor-associated disease affecting marine turtles worldwide and has been linked to ChHV5 infection, although disease expression depends on interactions among viral, host, and environmental factors. This study investigated the occurrence

Ahead of print

Oecologia Australis (ISSN: 2177-6199)
Ahead of print (https://revistas.ufrj.br/index.php/oa/issue/view/1109/showToc)
Article ID: AO#73365
Published online: 07 NOVEMBER 2026

of ChHV5 in blood and tumor samples from juvenile *Chelonia mydas* sampled across five coastal developmental habitats distributed along the Brazilian coast. A total of 157 individuals were examined. Fibropapillomatosis was recorded in 27.4% of turtles, with significant variation among sampling localities (Fisher's exact test, $p < 0.001$), and the highest prevalence was observed in Espírito Santo. ChHV5 DNA was detected in 8.3% of blood samples using the UL18 genetic target, including both individuals with and without visible FP, and blood-based viral detection was significantly associated with clinical FP status. Tumor samples collected opportunistically from seven turtles with clinically evident FP captured in Niterói, Rio de Janeiro, were all positive for ChHV5, reinforcing the association between ChHV5 and fibropapillomatous lesions. Viral detection occurred across multiple sampled localities, with no significant association between viral detection and sampling location. The UL18 assay showed a lower analytical detection limit than the UL30 assay under the conditions evaluated. Detection in turtles without visible FP supports viral occurrence beyond clinically apparent disease but does not establish infectiousness or transmission. Blood PCR can complement clinical surveillance, although negative blood results do not exclude infection. Conservation applications require integrated interpretation of clinical findings, molecular results, sampling effort, and habitat information.

Keywords: disease surveillance; herpesvirus; marine turtles; conservation medicine; subclinical infection

Ahead of print

INTRODUCTION

Sea turtles are key components of marine ecosystems and are widely recognized as sentinel species because they respond to environmental changes across broad spatial and temporal scales

(Bjorndal 1995, Musick & Limpus 1997, Aguirre & Lutz 2004). However, anthropogenic pressures such as habitat degradation, pollution, fisheries interactions, and climate-related changes have increasingly affected their survival, contributing to population declines worldwide (Lutz & Musick 1997, Lutz *et al.,* 2002, Bjorndal & Jackson 2003, Fuentes *et al.,* 2023).

Among the health threats affecting sea turtles, fibropapillomatosis (FP) is one of the most relevant. This disease is characterized by cutaneous and visceral tumors that may impair locomotion, feeding, and vision, compromising individual fitness and survival (Aguirre *et al.,* 1994, Herbst 1994, Jones *et al.,* 2016). FP has frequently been associated with anthropogenic pressures and environmental degradation and is considered a panzootic condition in marine turtle populations, particularly in juvenile green turtles, Chelonia mydas (Testudines, Cheloniidae), the species most frequently affected (Aguirre *et al.,* 1999, Work & Balazs 1999, Rossi *et al.,* 2016).

Strong evidence links fibropapillomatosis to ChHV5 (Scutavirus chelonidalpha5), which has been commonly detected in tumor tissues from infected sea turtles (Herbst *et al.,* 1995, Quackenbush *et al.,* 1998, Lackovich *et al.,* 1999, Lu *et al.,* 2000). However, the presence of the virus in itself does not cause clinical expression of the disease, which has been interpreted as the result of the interaction between host and environmental factors (Espinoza *et al.,* 2024).

Juvenile green turtles aggregate in coastal developmental habitats, areas where juvenile turtles concentrate during growth and development, making these habitats relevant settings for investigating both clinical FP and ChHV5 detection (Musick & Limpus 1997, Ene *et al.,* 2005). Viral DNA has also been detected in clinically healthy turtles, indicating that the absence of visible tumors does not necessarily indicate the absence of infection (Alfaro-Núñez *et al.,* 2014, Page-Karjian *et al.,* 2015).

Previous studies have detected ChHV5 DNA in blood samples from turtles with and without clinical FP, including individuals in rehabilitation in the southeastern United States

Ahead of print

Oecologia Australis (ISSN: 2177-6199)
Ahead of print (https://revistas.ufrj.br/index.php/oa/issue/view/1109/showToc)
Article ID: AO#73365
Published online: 07 NOVEMBER 2026

(Page-Karjian *et al.,* 2015). Together with evidence of viral DNA in clinically unaffected turtles (Alfaro-Núñez *et al.,* 2014) and the potential influence of host and environmental factors on disease expression (Jones *et al.,* 2016, Vanstreels *et al.,* 2023), these findings suggest that viral detection and clinical disease provide related but non-equivalent information. Assessing both measures in free-ranging juveniles across Brazilian coastal habitats can help characterize their correspondence and their complementary value for surveillance.

Based on this evidence, our hypothesis was that blood-based ChHV5 DNA detection would be associated with clinical FP but would not fully correspond to the presence or absence of visible tumors. Accordingly, we investigated clinical FP and ChHV5 DNA detection in 157 juveniles *Chelonia mydas* sampled across five coastal developmental habitats along the Brazilian coast. Specifically, we characterized FP prevalence and severity, evaluated the association between blood-based viral DNA detection and clinical FP, and examined geographic variation in these measures. In addition, tumor samples provided complementary molecular confirmation based on the UL18 and UL30 genetic targets, which were compared in terms of detectability efficiency and sensitivity limits under the conditions evaluated.

MATERIAL AND METHODS

Study areas, sampling and clinical procedures

Blood samples were collected from free-ranging juvenile *Chelonia mydas* at five locations along the Brazilian coast: Cassino Beach, Rio Grande, Rio Grande do Sul (RS) (32°10′S, 52°10′W; WGS84); Itapirubá Beach, Imbituba, Santa Catarina (SC) (28°14′S, 48°39′W; WGS84); Itaipu Beach, Niterói, Rio de Janeiro (RJ) (22°57′S, 43°03′W; WGS84); Santa Cruz, Aracruz, Espírito Santo (ES) (19°49′S, 40°16′W; WGS84); and Coroa Vermelha Island, Nova Viçosa, Bahia (BA) (17°53′S, 39°22′W; WGS84). These sites represent coastal developmental

Ahead of print

Oecologia Australis (ISSN: 2177-6199)
Ahead of print (https://revistas.ufrj.br/index.php/oa/issue/view/1109/showToc)
Article ID: AO#73365
Published online: 07 NOVEMBER 2026

habitats used by juvenile green turtles and are distributed along a broad latitudinal gradient in the southwestern Atlantic Ocean (Figure 1). Sampling campaigns were conducted between November 2021 and June 2022. The sample comprised 157 turtles: 33 from Cassino Beach (RS), 14 from Itapirubá Beach (SC), 20 from Itaipu Beach (RJ), 45 from Santa Cruz (ES), and 45 from Coroa Vermelha Island (BA).

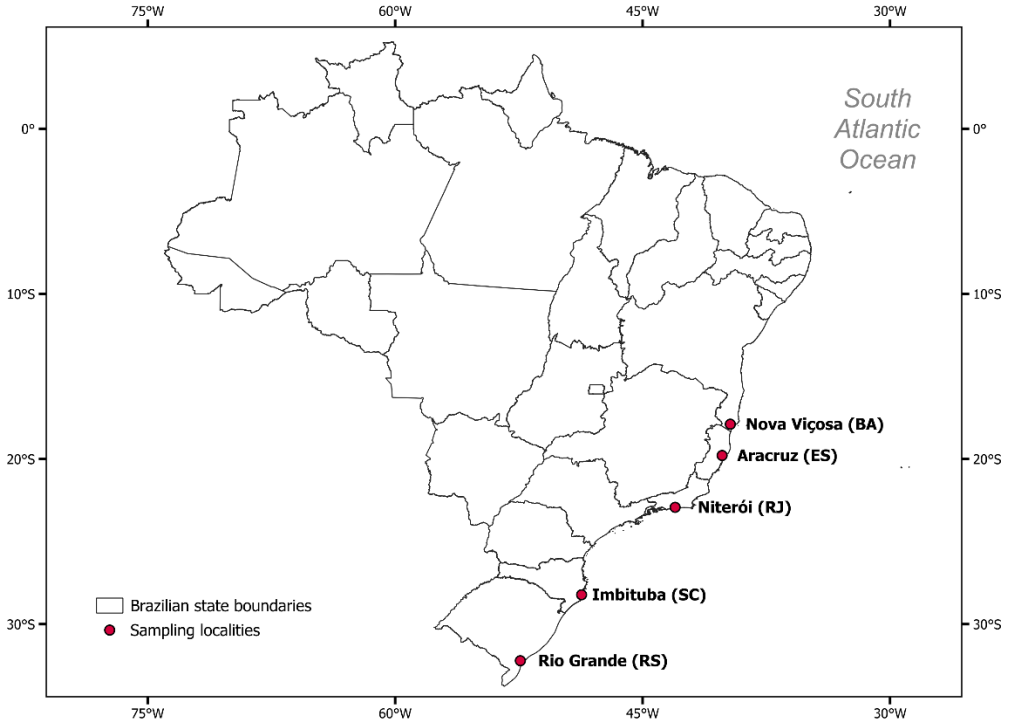

Figure 1. Geographic distribution of sampled juvenile green turtles (*Chelonia mydas*) in coastal developmental habitats along the Brazilian coast. Red dots indicate the sampling localities: Nova Viçosa (Bahia), Aracruz (Espírito Santo), Niterói (Rio de Janeiro), Itapirubá Beach, Imbituba (Santa Catarina), and Cassino Beach, Rio Grande (Rio Grande do Sul). Brazilian state boundaries are shown for geographic reference.

All procedures were approved by the Animal Ethics Committee (CEUA protocol no. 0206/2021) and authorized under SISBIO license no. 80646. Sampling activities in Niterói (RJ) were additionally conducted under SISBIO license no. 77721-1. All handling and sampling

Oecologia Australis (ISSN: 2177-6199)
Ahead of print (https://revistas.ufrj.br/index.php/oa/issue/view/1109/showToc)
Article ID: AO#73365
Published online: 07 NOVEMBER 2026

procedures were performed to minimize handling time and reduce animal stress during field activities.

Juvenile turtles were captured during scientific monitoring campaigns using techniques adapted to local environmental conditions and field logistics. In southern Brazil, gillnets were deployed and continuously monitored throughout capture activities. In Espírito Santo and Bahia, turtles were captured using monitored gillnets and, in shallow areas, cast nets. In Niterói, captures were performed using a beach seine deployed from a rowing canoe. Following capture, all animals underwent clinical examination, biometric assessment and biological sampling and were subsequently released at the capture site.

Animals were physically restrained for clinical examination and biometric measurements, including curved carapace length, curved carapace width, and body mass. Individuals were classified as juveniles based on curved carapace length and life-stage characteristics reported for *Chelonia mydas* in Brazilian coastal developmental habitats (Torezani *et al.,* 2010, Almeida *et al.,* 2011). To avoid duplicate sampling, all individuals were identified using metal flipper tags. Animals were examined for the presence of fibropapillomatosis (FP), and tumor location was recorded whenever lesions were observed.

Fibropapillomas were classified according to tumor size following Work & Balazs (1999), and the fibropapillomatosis index (FPI) was calculated according to Rossi *et al.,* (2016), integrating tumor size and anatomical distribution to classify disease severity into mild, moderate, and severe categories.

Whole blood samples (~2 mL) were collected from the cervical venous sinus using sterile syringes and transferred to EDTA-containing collection tubes for molecular analyses. Samples were stored at −20 °C until DNA extraction.

Ahead of print

Oecologia Australis (ISSN: 2177-6199)
Ahead of print (https://revistas.ufrj.br/index.php/oa/issue/view/1109/showToc)
Article ID: AO#73365
Published online: 07 NOVEMBER 2026

Tumor samples were collected opportunistically from seven turtles with clinically evident FP captured in Niterói (RJ), where field logistics and local permits allowed tissue collection. In addition to confirming the presence of ChHV5 in fibropapillomatous lesions, these samples provided a source of viral DNA for sequencing and molecular validation of the PCR assays employed in this study. Amplicons obtained from one tumor tissue sample were confirmed as ChHV5 through Sanger sequencing and BLAST analysis, and DNA from the confirmed positive sample was subsequently used as a positive control in the molecular assays.

One tissue sample per animal (~50 mg) was aseptically excised from externally visible fibropapilloma lesions using sterile instruments, prioritizing larger and easily accessible lesions to minimize handling time and sampling-associated stress. Sampled lesions included cutaneous regions of the cervical area, flippers, plastron, inguinal region, axillary region, and periocular tissues. Tissue fragments were preserved in absolute ethanol and stored at −20 °C until DNA extraction.

Molecular procedures

Genomic DNA was extracted from whole blood and tumor tissue samples using the DNeasy Blood & Tissue Kit (Qiagen®, Hilden, Germany) following the manufacturer's instructions. DNA concentration and purity were evaluated using a NanoDrop ND-1000 spectrophotometer (Thermo Fisher Scientific®, Wilmington, DE, USA) by measuring absorbance at 260/280 nm. DNA integrity was assessed by electrophoresis on 1.5% agarose gels stained with SYBR Safe DNA Gel Stain (Invitrogen®, Carlsbad, CA, USA), prepared in 1× TAE buffer (Tris-acetate-EDTA), and visualized under ultraviolet light.

Detection of ChHV5 DNA was performed by conventional PCR targeting the UL18 and UL30 genomic regions, corresponding to the capsid protein and DNA polymerase genes,

Ahead of print

respectively. PCR assays were carried out in an Eppendorf® Mastercycler® Nexus X2 thermocycler. Each reaction had a final volume of 25 µL containing 12.5 µL GoTaq® Green Master Mix 2× (Promega®, Madison, WI, USA), 0.5 µL of each primer (10 µM), 1 µL of genomic DNA template, and 10.5 µL ultrapure water.

Each PCR assay included DNA extracted from the ChHV5-positive fibropapilloma tissue sample confirmed by Sanger sequencing (individual ID 155) as a positive control and ultrapure water as a negative control.

Amplification conditions consisted of an initial denaturation step at 94 °C for 4 min, followed by 39 cycles at 94 °C for 30 s, 61 °C for 30 s, and 72 °C for 30 s, with a final extension at 72 °C for 7 min. The UL18 primer set targeting the capsid protein gene (forward: 5′-GTGGAACCCCGCCGGGTAAT-3′; reverse: 5′-TGATCCGGGCCGAGTAGCGC-3′), described by Alfaro-Núñez & Gilbert (2014), generated an expected amplicon of 140 bp. The UL30 primer set targeting the DNA polymerase gene (forward: 5′-AGCATCATCCAGGCCCACAATCT-3′; reverse: 5′-CGGCCAGTTCCGGCGCGTCGACCA-3′), described by Lu *et al.,* (2000), generated an expected amplicon of 445 bp.

The analytical sensitivity of the PCR assays was evaluated using serial ten-fold dilutions of genomic DNA extracted from the ChHV5-positive fibropapilloma tissue sample confirmed by Sanger sequencing (individual ID 155), which was used as the positive control. Dilutions ranging from 10 ng to 0.000001 ng were tested for both primer sets under the same PCR conditions described above. The analytical detection limit was defined as the lowest DNA concentration at which the expected amplicon was successfully amplified.

Amplified products were visualized by electrophoresis on 1.5% agarose gels stained with SYBR Safe DNA Gel Stain (Invitrogen®) in 1× TAE buffer and run at 90 V for 1 h. Gels were visualized using a Benchtop UV Transilluminator (Cambridge, UK) and analyzed with UVP®

Ahead of print

Oecologia Australis (ISSN: 2177-6199)
Ahead of print (https://revistas.ufrj.br/index.php/oa/issue/view/1109/showToc)
Article ID: AO#73365
Published online: 07 NOVEMBER 2026

VisionWorksLS™ software using a 1 Kb Plus DNA ladder (Invitrogen®) as a molecular size standard.

Amplicons obtained from the tumor tissue sample of one juvenile Chelonia mydas individual (ID 155), positive for both UL18 and UL30 genetic targets, were selected for sequencing. PCR products were purified using ExoSAP-IT® reagent (Affymetrix®, Thermo Fisher Scientific®) according to the manufacturer's instructions. Briefly, 8 µL of ExoSAP-IT reagent was added to 20 µL of PCR product, followed by incubation at 37 °C for 15 min and enzyme inactivation at 80 °C for 15 min in an Eppendorf® Mastercycler® Nexus X2 thermocycler. Purified products were prepared for bidirectional Sanger sequencing using forward and reverse primers and shipped under refrigerated conditions to the Biotechnology Institute (IBTEC), São Paulo State University (UNESP), Botucatu campus.

Sequences obtained from Sanger sequencing were edited and assembled using Chromas (Technelysium Pty Ltd., South Brisbane, Australia) and MEGA 11 (Tamura *et al.,* 2021). Consensus sequences were compared with sequences available in GenBank using the BLASTn algorithm available through the National Center for Biotechnology Information (NCBI) database to determine sequence identity relative to previously reported ChHV5 isolates.

Phylogenetic analyses were performed separately for the partial UL30 and UL18 sequences. Reference sequences were retrieved from GenBank based on BLASTn results and previously published phylogenetic studies of ChHV5. Sequences were aligned using MUSCLE in MEGA 11 (Tamura *et al.,* 2021), and identical ChHV5 sequences were collapsed into unique haplotypes to reduce redundancy. Homologous fragments of Testudinid alphaherpesvirus 3 (TeHV3; GenBank accession KM924292.1) were included as outgroups. The best-fitting nucleotide substitution model was selected according to the Bayesian Information Criterion (BIC). Maximum Likelihood phylogenetic trees were reconstructed using the Kimura 2-

Ahead of print

Oecologia Australis (ISSN: 2177-6199)
Ahead of print (https://revistas.ufrj.br/index.php/oa/issue/view/1109/showToc)
Article ID: AO#73365
Published online: 07 NOVEMBER 2026

parameter model, with uniform substitution rates among sites and 1,000 bootstrap replicates. Positions containing gaps or missing data were eliminated using complete deletion. The final alignments comprised 375 nucleotide positions for UL30 and 100 nucleotide positions for UL18.

Statistical analysis

Sample size and prevalence (%) were used to summarize fibropapillomatosis and ChHV5 detection, whereas absolute frequencies and proportions were used to describe the distribution of FP severity categories. Prevalence estimates were accompanied by 95% confidence intervals (95% CI) calculated using the Wilson score method.

Fisher's exact test was used to evaluate differences in FP prevalence, FP severity categories, and the prevalence of blood-based ChHV5 detection among sampling locations, as well as the association between clinical FP status (presence or absence of visible fibropapillomas) and blood-based viral detection. This test was selected because of the small sample sizes and low expected cell frequencies in some contingency tables.

For the association between clinical FP status and blood-based ChHV5 detection, the odds ratio (OR) and corresponding 95% confidence interval (95% CI) were calculated to estimate the magnitude of the association.

Fisher's exact tests and odds ratio calculations were performed using jamovi version 2.7 (The jamovi project 2025), based on R version 4.3.1 (R Core Team 2023). Statistical significance was set at $p < 0.05$. Comparisons between blood and tumor positivity were descriptive because tumor sampling was restricted to seven clinically affected turtles from one location. Analytical detection limits were compared using the dilution series and were not interpreted as estimates of clinical diagnostic sensitivity.

Ahead of print

Oecologia Australis (ISSN: 2177-6199)
Ahead of print (https://revistas.ufrj.br/index.php/oa/issue/view/1109/showToc)
Article ID: AO#73365
Published online: 07 NOVEMBER 2026

RESULTS

A total of 157 juvenile *Chelonia mydas* were sampled across five coastal developmental habitats distributed along the Brazilian coast (Figure 1). Fibropapillomatosis (FP) was observed in 27.4% (43/157) of sampled turtles. FP prevalence differed significantly among sampled localities (Fisher's exact test, $p < 0.001$). The highest prevalence was recorded in Aracruz, Espírito Santo (53.3%; 24/45), whereas lower prevalence values were observed in Nova Viçosa, Bahia (8.9%; 4/45) and Cassino, Rio Grande do Sul (9.1%; 3/33) (Table 1).

Table 1. Prevalence of fibropapillomatosis (FP) and blood-based ChHV5 detection using the UL18 genetic target in juvenile *Chelonia mydas* according to sampling location in Brazil. Prevalence values are presented as percentages with 95% confidence intervals (95% CI), calculated using the Wilson method. State abbreviations: BA = Bahia; ES = Espírito Santo; RJ = Rio de Janeiro; SC = Santa Catarina; RS = Rio Grande do Sul.

Sampling location	State	Sample size (n)	FP prevalence, % (95% CI)	Blood-based ChHV5 detection prevalence (UL18), % (95% CI)
Nova Viçosa	BA	45	8.9 (3.5–20.7)	6.7 (2.3–17.9)
Aracruz	ES	45	53.3 (39.1–67.1)	15.6 (7.7–28.8)
Niterói	RJ	20	35.0 (18.1–56.7)	10.0 (2.8–30.1)
Itapirubá	SC	14	35.7 (16.3–61.2)	7.1 (1.3–31.5)
Cassino	RS	33	9.1 (3.1–23.6)	0.0 (0.0–10.4)
Total		**157**	**27.4 (21.0–34.8)**	**8.3 (4.9–13.7)**

Among turtles with clinically evident FP, disease severity was predominantly classified as mild (69.8%; 30/43), followed by moderate (18.6%; 8/43) and severe forms (11.6%; 5/43) (Figure 2). No association was observed between sampled localities and FP severity categories (Fisher's exact test, p = 0.961).

Ahead of print

Oecologia Australis (ISSN: 2177-6199)
Ahead of print (https://revistas.ufrj.br/index.php/oa/issue/view/1109/showToc)
Article ID: AO#73365
Published online: 07 NOVEMBER 2026

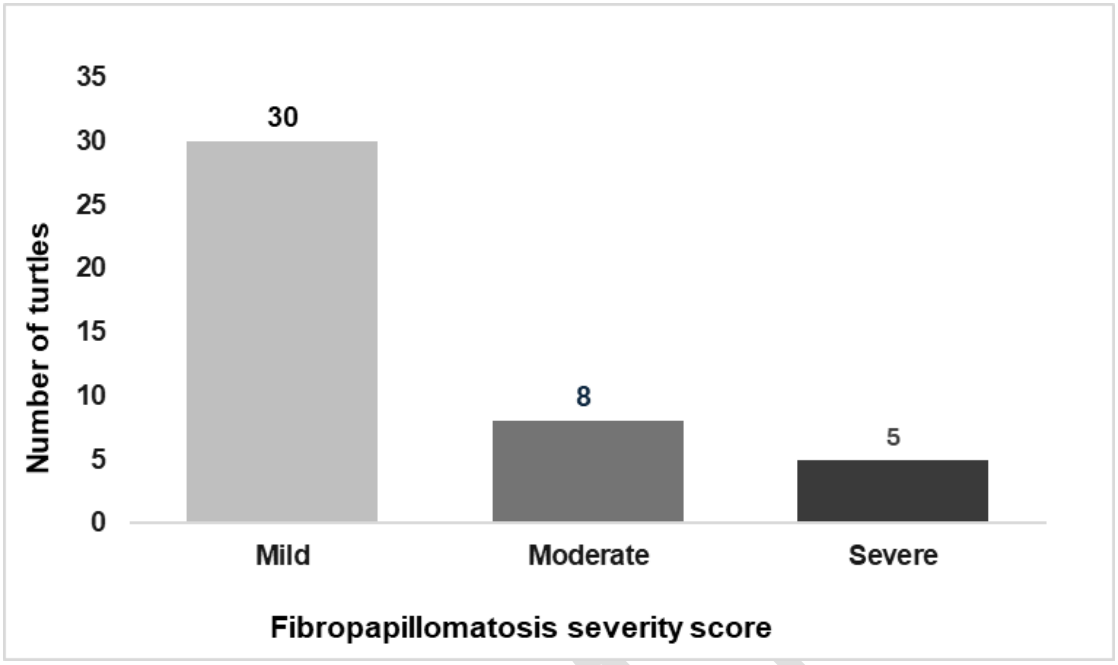

Figure 2. Distribution of fibropapillomatosis severity categories among juvenile green turtles (*Chelonia mydas*) with clinically evident FP along the Brazilian coast. Numbers above bars indicate the number of affected individuals classified as mild, moderate, or severe according to the fibropapillomatosis index (FPI).

ChHV5 DNA was detected in 8.3% (13/157) of blood samples using the UL18 genetic target (Table 1). Viral DNA was detected in both turtles with and without clinically evident FP. No amplification was observed in blood samples using the UL30 genetic target.

Blood-based detection of ChHV5 using the UL18 genetic target was significantly associated with clinical FP status. Turtles with clinically evident FP showed a higher frequency of viral detection in blood samples than turtles without clinically evident FP (Fisher's exact test, $p = 0.046$). Turtles with clinically evident FP had 3.5-fold higher odds of blood-based ChHV5 detection than turtles without clinically evident FP (OR = 3.50; 95% CI: 1.10–11.10) (Table 2). Blood-based ChHV5 detection did not differ significantly among sampling locations (Fisher's exact test, $p = 0.123$) (Table 1).

Ahead of print

Oecologia Australis (ISSN: 2177-6199)
Ahead of print (https://revistas.ufrj.br/index.php/oa/issue/view/1109/showToc)
Article ID: AO#73365
Published online: 07 NOVEMBER 2026

Table 2. Prevalence of blood-based ChHV5 detection using the UL18 genetic target according to clinical fibropapillomatosis status in juvenile *Chelonia mydas* from Brazil. Prevalence values are presented as percentages with 95% confidence intervals (95% CI), calculated using the Wilson method.

Clinical FP status	Sample size (n)	Blood-based ChHV5 detection prevalence (UL18), % (95% CI)
With clinically evident FP	43	16.3 (8.1–30.0)
Without clinically evident FP	114	5.3 (2.4–11.0)

Tumor tissue samples were collected opportunistically from turtles with clinically evident FP captured in Niterói, Rio de Janeiro. All tumor tissue samples tested positive for ChHV5 using the UL18 genetic target (7/7; 100%), whereas amplification using UL30 was observed in 5/7 (71.4%) tumor samples (Table 3). Representative electrophoretic profiles of amplified products obtained using both molecular targets are shown in Figure 3. Analytical sensitivity assays demonstrated a lower detection limit for UL18 than for UL30. The UL18 assay amplified the expected 140 bp fragment down to 0.0001 ng of genomic DNA, whereas UL30 amplified the expected 445 bp fragment down to 1 ng (Figure 4).

Table 3. Detection of ChHV5 using the UL18 and UL30 genetic targets in tumor tissue samples collected opportunistically from juvenile *Chelonia mydas* with clinically evident fibropapillomatosis captured in Niterói, Rio de Janeiro, Brazil.

Animal ID	UL18	UL30
142	Positive	Negative
145	Positive	Positive
146	Positive	Positive
149	Positive	Negative
153	Positive	Positive
155	Positive	Positive
157	Positive	Positive

Ahead of print

Oecologia Australis (ISSN: 2177-6199)
Ahead of print (https://revistas.ufrj.br/index.php/oa/issue/view/1109/showToc)
Article ID: AO#73365
Published online: 07 NOVEMBER 2026

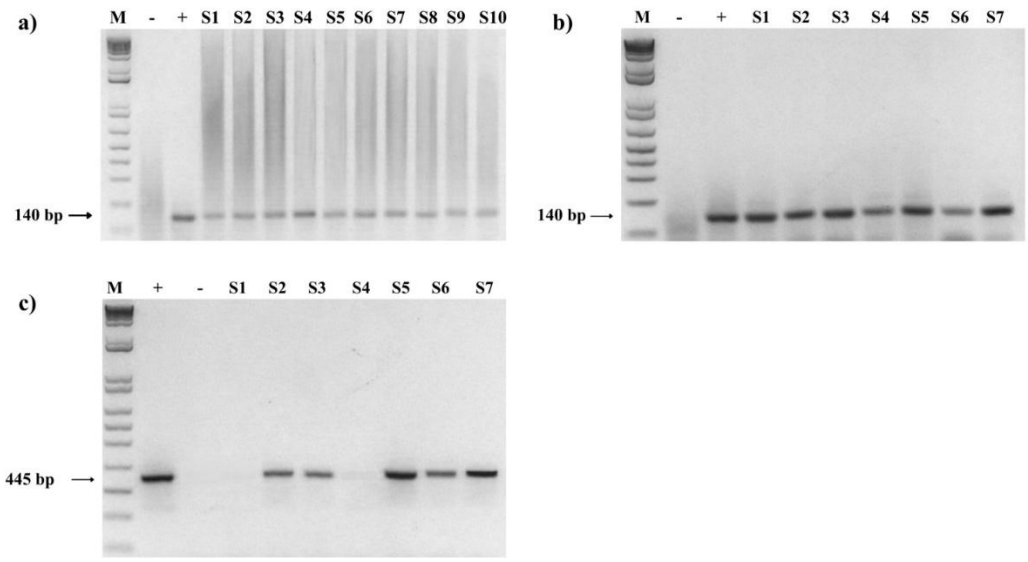

Figure 3. Representative agarose gel electrophoresis profiles of PCR products for molecular detection of ChHV5 in juvenile green turtles (*Chelonia mydas*). (**a**) Amplification of the expected 140 bp fragment using the UL18 genetic target in blood samples; (**b**) amplification of the expected 140 bp fragment using the UL18 genetic target in tumor tissue samples; (**c**) amplification of the expected 445 bp fragment using the UL30 genetic target in tumor tissue samples. M: molecular weight marker; (+): positive control; (–): negative control; S1–S10: individual blood samples in panel (**a**); S1–S7: individual tumor tissue samples in panels (**b**) and (**c**). Expected fragment sizes are indicated on the left side of each panel.

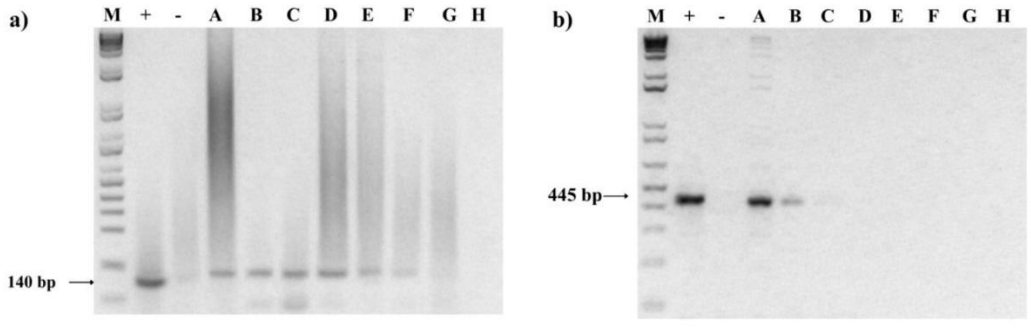

Figure 4. Analytical sensitivity assay of conventional PCR targeting ChHV5 using serial ten-fold dilutions of genomic DNA extracted from ChHV5-positive fibropapilloma tissue. (**a**) Amplification of the UL18 genetic target (140 bp fragment); (**b**) amplification of the UL30 genetic target (445 bp fragment). M: molecular weight marker; (+): positive control; (–): negative control; A–H: serial ten-fold dilutions of genomic DNA corresponding to 10, 1, 0.1, 0.01, 0.001, 0.0001, 0.00001, and 0.000001 ng, respectively. The analytical detection limit was 0.0001 ng for UL18 and 1 ng for UL30.

Oecologia Australis (ISSN: 2177-6199)
Ahead of print (https://revistas.ufrj.br/index.php/oa/issue/view/1109/showToc)
Article ID: AO#73365
Published online: 07 NOVEMBER 2026

Sequenced amplicons obtained from a tumor sample of a single juvenile *Chelonia mydas* individual (ID 155) confirmed ChHV5 identity. The partial UL30 sequence (376 nt; GenBank accession QB037782) showed 100% identity with ChHV5 sequences from Brazil (MH144348.1, MH101744.1, KU048040.1, KR048335.1, MT272982.1, JN938586.1, and MK953552.1), Puerto Rico (JN580279.1), and São Tomé and Príncipe (HQ000007.1, HM348896.1, and HM348895.1). The 100-nt UL18 consensus sequence (GenBank accession QB037783) showed 100% identity with LC899768.1, KY933584.1, KY933583.1, OQ189660.1, OQ189658.1, and NC_075701.1, and 99.01% identity with LC536649.1. Phylogenetic analyses were consistent with the BLASTn results. In the UL30 tree (Figure 5), the ID 155 sequence was included in haplotype H1 together with 11 identical ChHV5 reference sequences (n = 12). H1 clustered with MN563740.1 with 78% bootstrap support and was positioned within a broader ChHV5 clade, whereas TeHV3 (KM924292.1) formed the outgroup. In the UL18 tree (Figure 6), the ID 155 sequence was included in haplotype H1 together with eight identical ChHV5 reference sequences (n = 9) and clustered with H2 (LC536649.1) with 99% bootstrap support. H3 (AY644454.1) was resolved separately within ChHV5, whereas TeHV3 (KM924292.1) formed the outgroup. Together, these analyses supported the molecular identification of both partial viral fragments as ChHV5. DNA from the ChHV5-confirmed tumor tissue sample was subsequently used as a positive control for the molecular assays performed in this study.

Ahead of print

Oecologia Australis (ISSN: 2177-6199)
Ahead of print (https://revistas.ufrj.br/index.php/oa/issue/view/1109/showToc)
Article ID: AO#73365
Published online: 07 NOVEMBER 2026

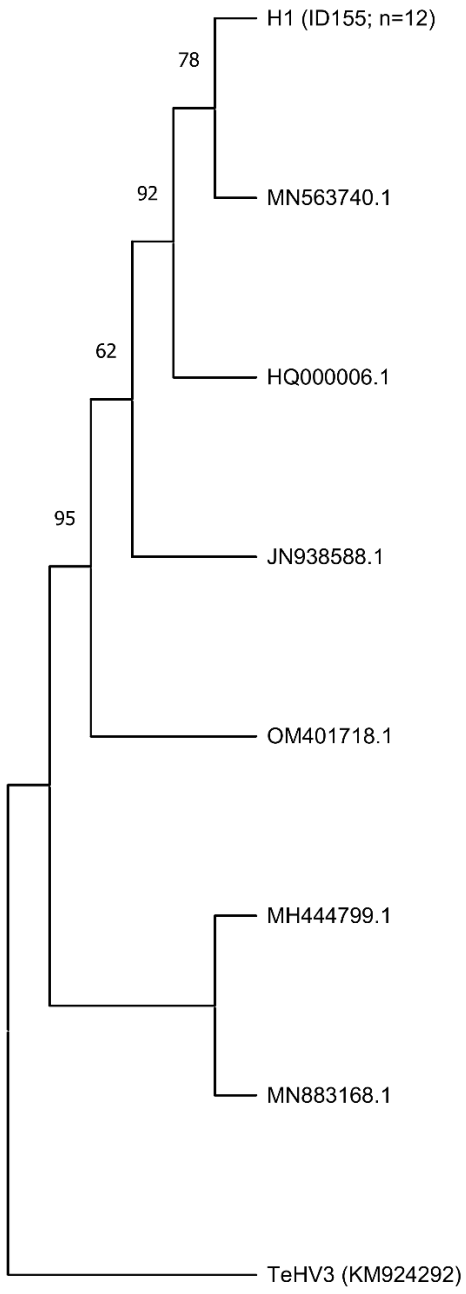

Figure 5. Maximum Likelihood phylogenetic tree based on a 375-nt partial UL30 region of ChHV5. The analysis was performed in MEGA 11 using the Kimura 2-parameter model, with 1,000 bootstrap

Oecologia Australis (ISSN: 2177-6199)
Ahead of print (https://revistas.ufrj.br/index.php/oa/issue/view/1109/showToc)
Article ID: AO#73365
Published online: 07 NOVEMBER 2026

replicates and complete deletion of sites containing gaps or missing data. Bootstrap values ≥ 50% are shown next to the branches. Testudinid alphaherpesvirus 3 (TeHV3; KM924292.1) was used as outgroup. Haplotype H1 includes the sequence obtained from individual ID 155 and 11 identical ChHV5 reference sequences (n = 12).

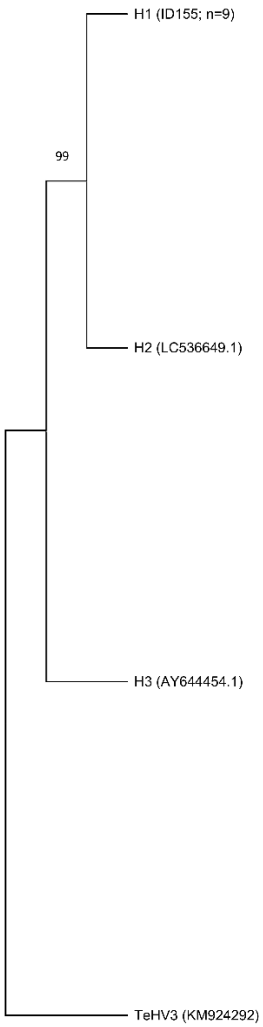

Figure 6. Maximum Likelihood phylogenetic tree based on a 100-nt partial UL18 region of ChHV5. The analysis was performed in MEGA 11 using the Kimura 2-parameter model, with 1,000 bootstrap replicates and complete deletion of sites containing gaps or missing data. Bootstrap values ≥ 50% are

Oecologia Australis (ISSN: 2177-6199)
Ahead of print (https://revistas.ufrj.br/index.php/oa/issue/view/1109/showToc)
Article ID: AO#73365
Published online: 07 NOVEMBER 2026

shown next to the branches. Testudinid alphaherpesvirus 3 (TeHV3; KM924292.1) was used as outgroup. Haplotype H1 includes the sequence obtained from individual ID 155 and eight identical ChHV5 reference sequences (n = 9).

DISCUSSION

Fibropapillomatosis (FP) is a globally distributed disease affecting marine turtles and is currently recognized as a major threat to sea turtle populations, particularly in coastal developmental habitats used by juvenile *Chelonia mydas* (Herbst 1994, Baptistotte 2007, Jones *et al.,* 2016). In the present study, FP was observed in 27.4% of individuals, confirming its occurrence among sampled coastal developmental habitats and reinforcing previous evidence that the disease is widely distributed in Brazilian green turtle populations (Baptistotte 2007, Silva 2019). Previous Brazilian studies have reported substantial geographic variation in prevalence, reinforcing the heterogeneous distribution of the disease among coastal habitats. Baptistotte (2007), analyzing more than 10,000 sea turtles along the Brazilian coast, reported an overall prevalence of 15.41% in *Chelonia mydas*, with marked regional variation ranging from 5.96% in Rio de Janeiro to 36.94% in Ceará. More recently, Silva (2019) also reported heterogeneous prevalence patterns among juvenile green turtles from southeastern Brazil, reinforcing regional variability in FP occurrence.

Marked geographic differences were observed among sampling locations, with prevalence ranging from 8.9% in Bahia to 53.3% in Espírito Santo. Compared with previous Brazilian reports, the prevalence observed in Espírito Santo (53.3%) and Rio de Janeiro (35.0%) exceeded values previously described for these regions, whereas Bahia showed a comparatively lower prevalence (Baptistotte 2007). This heterogeneity supports previous evidence suggesting

Ahead of print

Oecologia Australis (ISSN: 2177-6199)
Ahead of print (https://revistas.ufrj.br/index.php/oa/issue/view/1109/showToc)
Article ID: AO#73365
Published online: 07 NOVEMBER 2026

that FP distribution is spatially variable and likely influenced by multiple interacting factors rather than viral exposure alone (Jones *et al.,* 2016, Manes *et al.,* 2022).

The high FP prevalence observed in Santa Cruz, Aracruz, should also be considered in the context of the region's history of environmental disturbance. Coastal protected areas in this region, including the Santa Cruz Wildlife Refuge and the Costa das Algas Environmental Protection Area, were affected by the November 2015 Fundão tailings dam collapse, with subsequent assessments documenting deterioration in environmental quality and impacts on the biota (ICMBio 2023). Studies including sites in Aracruz have also documented metal accumulation and associated physiological changes in mangrove vegetation (D'Addazio *et al.,* 2023), as well as trace elements in beach-cast seaweeds collected in 2022, with elemental profiles interpreted as indicative of mining-related contamination (Basilio *et al.,* 2026).

These findings raise the possibility that environmental stressors associated with the disaster may have favored FP expression in the turtles in this coastal habitat. This possible environmental contribution is consistent with evidence that environmental conditions may influence FP manifestation in green turtles along the Espírito Santo coast (Vanstreels *et al.,* 2023). However, the present study did not assess environmental contaminants or individual exposure, and its cross-sectional design cannot establish a relationship between the disaster and the observed FP prevalence. The potential contribution of disaster-related stressors therefore remains a hypothesis requiring targeted investigation alongside other environmental and host-related factors.

The predominance of mild FP cases observed in this study is consistent with previous reports from Brazilian populations, where smaller tumors and less severe disease presentations have been frequently observed in juvenile green turtles (Baptistotte 2007, Rossi *et al.,* 2016). Variation in FP clinical expression may reflect the multifactorial nature of the disease, involving interactions among host-related and environmental factors (Jones *et al.,* 2016, Manes *et al.,* 2022).

Ahead of print

Oecologia Australis (ISSN: 2177-6199)
Ahead of print (https://revistas.ufrj.br/index.php/oa/issue/view/1109/showToc)
Article ID: AO#73365
Published online: 07 NOVEMBER 2026

The low proportion of severe cases could also reflect selective loss of severely affected turtles through mortality or differences in their availability for capture. In a rehabilitation setting, lesion characteristics, including ocular involvement, were associated with survival outcomes (Page-Karjian *et al.,* 2014). That evidence makes survival-related sampling effects plausible, but it does not establish that they occurred in our free-ranging sample. Without longitudinal follow-up or mortality data, we cannot distinguish these explanations from differences in disease progression or regression.

The partial association between blood-based ChHV5 DNA detection and clinical FP is consistent with our hypothesis. Most of the turtles with visible FP had negative blood PCR results, whereas viral DNA was detected in turtles without visible lesions. Thus, clinical examination and blood PCR provided complementary information across the 157 juveniles sampled in five coastal habitats, but a single diagnostic method could not characterize an individual infection status. All seven tumor samples were positive for ChHV5 using UL18, supporting the association between the virus and fibropapillomatous lesions. However, the limited tumor sampling does not allow a reliable assessment of agreement between blood- and tumor-based detection. Blood-based UL18 detection was significantly associated with clinical FP status (OR = 3.50; 95% CI: 1.10–11.10), although the wide confidence interval indicates uncertainty in the magnitude of this association. In addition, the cross-sectional design could not determine whether blood positivity preceded or followed tumor development.

Detection of viral DNA in turtles without visible FP is consistent with previous reports (Alfaro-Núñez *et al.,* 2014, Page-Karjian *et al.,* 2015) but it is not enough to consider these animals as natural reservoirs or to indicate that they will subsequently develop tumors. The present data cannot distinguish persistent infection, reactivation, or a transient episode of detectable viral DNA. Longitudinal sampling would be necessary to investigate these alternatives.

Ahead of print

Oecologia Australis (ISSN: 2177-6199)
Ahead of print (https://revistas.ufrj.br/index.php/oa/issue/view/1109/showToc)
Article ID: AO#73365
Published online: 07 NOVEMBER 2026

Detection of ChHV5 DNA in blood should be distinguished from detection of infectious virus or active viral replication. Page-Karjian *et al.,* (2015) described blood-associated viral DNA in turtles with different clinical histories. In the present study, conventional PCR documented DNA detection in the samples but did not measure viral load, establish infectivity, or identify a transmission route.

Several molecular targets have been employed for ChHV5 detection and characterization, including genes encoding DNA polymerase (UL30), capsid protein (UL18), and glycoproteins (UL22 and UL27) (Loganathan *et al.,* 2021, Espinoza *et al.,* 2024). Among these, UL30 has been widely used for molecular detection and characterization of ChHV5 (Chaves *et al.,* 2017). In the present study, however, the UL18 assay showed higher analytical sensitivity than UL30 under the conditions evaluated, amplifying ChHV5 DNA at substantially lower amounts of total template DNA. These limitations are based on the total DNA extracted from one positive tumor sample rather than amplification of the viral genome. The lower analytical detection limit observed for UL18 compared with UL30 applies specifically to the PCR assays performed using serial dilutions of total DNA extracted from the ChHV5-positive tumor sample (ID 155), under the amplification conditions described in Materials and Methods. This finding does not establish an intrinsic sensitivity difference between the genetic targets or provide a validated estimate of clinical diagnostic sensitivity.

The high tumor positivity and limited blood positivity illustrate the need to consider sample type and assay choice when interpreting detection outcomes. However, the seven tumor samples came only from clinically affected turtles in Niterói, whereas the blood analysis included turtles with different clinical states from all five sites. Their overall positivity proportions should therefore not be used as a controlled comparison of diagnostic performance between matrices. Likewise, the absence of UL30 amplification in blood does not demonstrate the absence of

Ahead of print

ChHV5; it must be interpreted alongside the lower analytical detection capability of that assay under the conditions evaluated.

Comparing diagnostic methods in field surveillance, clinical examination and blood PCR address complementary questions. The clinical examination of visible FP tumors during capture permits the classification of the level of severity without molecular laboratory processing. In contrast, PCR analyses can add evidence of viral DNA in turtles without visible tumors but require blood collection, sample preservation, DNA extraction, reagents, proper equipment, and trained personnel. Thus, the choice of the method should be considered according to the surveillance objective; no economic evaluation was conducted here. A practical approach would combine standardized clinical monitoring with molecular sampling according to a predefined surveillance design and available resources. Negative blood PCR results should not be used to classify turtles as uninfected or to exclude disease in animals with visible lesions.

Despite the geographic distribution of ChHV5-positive individuals among sampled localities, no significant association was observed between viral presence and sampling location. Interpretation of geographic patterns should be approached cautiously because juvenile sea turtles may move among coastal developmental habitats, preventing sampled localities from being interpreted as fully independent epidemiological units. Movement among geographically distinct habitats is consistent with the population connectivity described for marine turtles (Bowen & Karl 2007). Consistent with this ecological connectivity, phylogeographic analyses of ChHV5 have shown that viral geographic patterns partially reflect sea turtle movements and have provided evidence of viral gene flow among geographically distant regions (Patrício *et al.,* 2012). Therefore, connectivity among coastal developmental habitats should be considered when interpreting spatial patterns of ChHV5 circulation. Sequence analysis confirmed ChHV5 identity and demonstrated high similarity between the partial UL18 and UL30 sequences obtained in this

Ahead of print

study and ChHV5 sequences previously reported from different geographic regions. Phylogenetic analyses further supported the molecular identification of both fragments as ChHV5. The UL30 sequence from individual ID 155 was included in a haplotype shared with 11 identical reference sequences and clustered with other ChHV5 sequences, whereas the UL18 sequence grouped with closely related ChHV5 haplotypes. However, because both analyses were based on short partial viral fragments obtained from a single individual, particularly the 100-nt UL18 fragment, the resulting phylogenetic relationships should be interpreted cautiously and should not be considered evidence of geographic structuring or broader viral evolutionary patterns.

Some limitations should be considered when interpreting these results. Interpretation of geographic differences should also consider unequal sampling effort among locations, which may influence prevalence estimates and reduce comparability among sampling sites. The relatively low number of positive blood samples may have limited the statistical power to detect spatial patterns in viral detection. Tumor tissue sampling was restricted to turtles with clinically evident FP captured in Niterói and should therefore be interpreted as complementary molecular confirmation rather than as a geographically representative assessment of tumor-associated ChHV5 occurrence. In addition, the cross-sectional design does not allow inference about temporal dynamics of infection, latency, and disease progression. Furthermore, environmental variables were not directly measured, preventing causal interpretations regarding anthropogenic influences on disease occurrence. Future studies integrating longitudinal sampling, environmental variables, and host conditions are necessary to better understand the ecological drivers of fibropapillomatosis.

In conclusion, blood-based ChHV5 DNA detection was associated with clinical FP but did not fully correspond to visible disease, consistent with our hypothesis that viral circulation occurs in both clinically affected and asymptomatic individuals. The paired clinical and molecular

Ahead of print

assessments of 157 juvenile green turtles across five Brazilian coastal developmental habitats provided complementary information for surveillance. Clinical examination documented spatial differences in visible disease, whereas blood PCR identified viral DNA in some turtles with and without visible FP. Blood PCR may therefore supplement repeated health monitoring, but its limited positivity among clinically affected turtles prevents its use as a standalone indicator of infection or disease burden. Identification of conservation priorities should combine clinical prevalence and severity, repeated sampling, sampling effort, and independent habitat information rather than rely exclusively on blood positivity.

ACKNOWLEDGEMENTS

The authors thank Projeto Caminho Marinho, Projeto Chelonia mydas, and Projeto Aruanã for their collaboration in field activities, logistical support, and assistance with sea turtle monitoring and biological sampling along the Brazilian coast. This study was partially supported by a master's scholarship granted by the Coordenação de Aperfeiçoamento de Pessoal de Nível Superior (CAPES), Brazil.

REFERENCES

Aguirre, A. A., & Lutz, P. L. 2004. Marine turtles as sentinels of ecosystem health: is fibropapillomatosis an indicator? *EcoHealth*, 1(3), 275–283. DOI: 10.1007/s10393-004-0097-3.

Aguirre, A. A., Balazs, G. H., Zimmerman, B., & Spraker, T. R. 1994. Evaluation of Hawaiian green turtles (*Chelonia mydas*) for potential pathogens associated with fibropapillomas. *Journal of Wildlife Diseases*, 30(1), 8–15. DOI: 10.7589/0090-3558-30.1.8.

Ahead of print

Aguirre, A. A., Spraker, T. R., Balazs, G. H., & Zimmerman, B. 1999. Pathology of fibropapillomatosis in olive ridley turtles (*Lepidochelys olivacea*) nesting in Costa Rica. *Journal of Aquatic Animal Health*, 11(3), 283–289. DOI: 10.1577/1548-8667(1999)011<0283:POFIOR>2.0.CO;2.

Alfaro-Núñez, A., & Gilbert, M. T. P. 2014. Validation of a sensitive PCR assay for the detection of Chelonid fibropapilloma-associated herpesvirus in latent turtle infections. *Journal of Virological Methods*, 206, 38–41. DOI: 10.1016/j.jviromet.2014.05.019.

Alfaro-Núñez, A., Bertelsen, M. F., Bojesen, A. M., Rasmussen, I., Zepeda-Mendoza, M. L., & Gilbert, M. T. P. 2014. Global distribution of Chelonid fibropapilloma-associated herpesvirus among clinically healthy sea turtles. *BMC Evolutionary Biology*, 14, 206. DOI: 10.1186/s12862-014-0206-z.

Almeida, A. P., Santos, A. J. B., Thomé, J. C. A., Bellini, C., Baptistotte, C., Marcovaldi, M. Â., Santos, A. S., & Lopez, M. 2011. Avaliação do Estado de Conservação da Tartaruga Marinha *Chelonia mydas* (Linnaeus, 1758) no Brasil. *Biodiversidade Brasileira*, 1(1), 12–19.

Baptistotte, C. 2007. Caracterização espacial e temporal da fibropapilomatose em tartarugas marinhas da costa brasileira. Doctoral thesis. Universidade de São Paulo, Piracicaba, Brazil. p. 63.

Basilio, T. H., Nunes, B. R. R., Neto, A. E., Bonemann, D. H., Bueno, D. T., Fujii, M. T., Alonso, I., Lima, A. T., Rodrigues Junior, W. A., Costa, E. S., & Rodrigues Neto, R. 2026. Trace Metal Concentration in Beach-Cast Seaweeds from Southeastern Brazil Indicates the Legacy of the Mining Industry. Phycology, 6(2), 44. DOI: 10.3390/phycology6020044.

Bjorndal, K. A. 1995. *Biology and conservation of sea turtles*. Washington, DC: Smithsonian Institution Press: p. 615.

Ahead of print

Bjorndal, K. A., & Jackson, J. B. C. 2003. Roles of sea turtles in marine ecosystems: reconstructing the past. In: P. L. Lutz, J. A. Musick, & J. Wyneken (Eds.), *The Biology of Sea Turtles*. Vol. II. pp. 259–273. Boca Raton, FL: CRC Press.

Bowen, B. W., & Karl, S. A. 2007. Population genetics and phylogeography of sea turtles. *Molecular Ecology*, 16(23), 4886–4907. DOI: 10.1111/j.1365-294X.2007.03542.x.

Chaves, A., Aguirre, A. A., Blanco-Peña, K., Moreira-Soto, A., Monge, O., Torres, A. M., Soto-Rivas, J. L., Lu, Y., Chacón, D., Fonseca, L., Jiménez, M., Gutiérrez-Espeleta, G., & Lierz, M. 2017. Examining the role of transmission of Chelonid Alphaherpesvirus 5. *EcoHealth*, 14(3), 530–541. DOI: 10.1007/s10393-017-1248-7.

D'Addazio, V., Tognella, M. M. P., Fernandes, A. A., Falqueto, A. R., da Rosa, M. B., Gontijo, I., & de Oliveira, M. A. 2023. Impact of Metal Accumulation on Photosynthetic Pigments, Carbon Assimilation, and Oxidative Metabolism in Mangroves Affected by the Fundão Dam Tailings Plume. Coasts, 3(2), 125–144. DOI: 10.3390/coasts3020008.

Ene, A., Su, M., Lemaire, S., Rose, C., Schaff, S., Moretti, R., Lenz, J., & Herbst, L. H. 2005. Distribution of chelonid fibropapilloma-associated herpesvirus variants in Florida: molecular genetic evidence for infection of turtles following recruitment to neritic developmental habitats. *Journal of Wildlife Diseases*, 41(3), 489–497. DOI: 10.7589/0090-3558-41.3.489.

Espinoza, J., Alfaro-Núñez, A., Cedillo-Peláez, C., Fernández-Sanz, H., Mancini, A., Zavala-Norzagaray, A. A., Ley-Quiñonez, C. P., Santacruz López, E., Garcia-Bereguiain, M. A., Aguirre, A. A., & Reséndiz, E. 2024. Epidemiology of marine turtle fibropapillomatosis and tumour-associated chelonid alphaherpesvirus 5 (ChHV5; *Scutavirus chelonidalpha5*) in north-western Mexico: a scoping review implementing the One Health approach.

Ahead of print

Veterinary Research Communications, 48(5), 2943–2961. DOI: 10.1007/s11259-024-10429-6.

Fuentes, M. M. P. B., McMichael, E., Kot, C. Y., Silver-Gorges, I., Wallace, B. P., Godley, B. J., Brooks, A. M. L., Ceriani, S. A., Cortés-Gómez, A. A., Dawson, T. M., Dodge, K. L., Flint, M., Jensen, M. P., Komoroske, L. M., Kophamel, S., Lettrich, M. D., Long, C. A., Nelms, S. E., Patrício, A. R., Robinson, N. J., Seminoff, J. A., Ware, M., Whitman, E. R., Chevallier, D., Clyde-Brockway, C. F., Korgonkar, S. A., Mancini, A., Mello-Fonseca, J., Monsinjon, J. R., Neves-Ferreira, I., Ortega, A. A., Patel, S. H., Pfaller, J. B., Ramirez, M. D., Raposo, C., Smith, C. E., Abreu-Grobois, F. A., & Hays, G. C. 2023. Key issues in assessing threats to sea turtles: knowledge gaps and future directions. *Endangered Species Research*, 52, 303–341. DOI: 10.3354/esr01278.

Herbst, L. H. 1994. Fibropapillomatosis of marine turtles. *Annual Review of Fish Diseases*, 4, 389–425. DOI: 10.1016/0959-8030(94)90037-X.

Herbst, L. H., Jacobson, E. R., Moretti, R., Brown, T., Sundberg, J. P., & Klein, P. A. 1995. Experimental transmission of green turtle fibropapillomatosis using cell-free tumor extracts. *Diseases of Aquatic Organisms*, 22(1), 1–12. DOI: 10.3354/dao022001.

ICMBio — Instituto Chico Mendes de Conservação da Biodiversidade. 2023. Plano de manejo: Refúgio de Vida Silvestre de Santa Cruz e Área de Proteção Ambiental Costa das Algas. Brasília, DF: ICMBio. Retrieved on October 15, 2026, from https://www.gov.br/icmbio/pt-br/assuntos/biodiversidade/unidade-de-conservacao/unidades-de-biomas/marinho/lista-de-ucs/revis-de-santa-cruz/informacoes-da-unidade-de-conservacao/planos-de-manejo

Jones, K., Ariel, E., Burgess, G., & Read, M. 2016. A review of fibropapillomatosis in green turtles (*Chelonia mydas*). *The Veterinary Journal*, 212, 48–57. DOI: 10.1016/j.tvjl.2015.10.041.

Ahead of print

Lackovich, J. K., Brown, D. R., Homer, B. L., Garber, R. L., Mader, D. R., Moretti, R. H., Patterson, A. D., Herbst, L. H., Oros, J., Jacobson, E. R., Curry, S. S., & Klein, P. A. 1999. Association of herpesvirus with fibropapillomatosis of the green turtle *Chelonia mydas* and the loggerhead turtle *Caretta caretta* in Florida. *Diseases of Aquatic Organisms*, 37(2), 89–97. DOI: 10.3354/dao037089.

Loganathan, A. L., Palaniappan, P., & Subbiah, V. K. 2021. First evidence of Chelonid Herpesvirus 5 (ChHV5) infection in green turtles (*Chelonia mydas*) from Sabah, Borneo. *Pathogens*, 10(11), 1404. DOI: 10.3390/pathogens10111404.

Lu, Y., Wang, Y., Yu, Q., Aguirre, A. A., Balazs, G. H., Nerurkar, V. R., & Yanagihara, R. 2000. Detection of herpesviral sequences in tissues of green turtles with fibropapilloma by polymerase chain reaction. *Archives of Virology*, 145(9), 1885–1893. DOI: 10.1007/s007050070063.

Lutz, P. L., & Musick, J. A. 1997. *The Biology of Sea Turtles*. Boca Raton, FL: CRC Press: p. 446.

Lutz, P. L., Musick, J. A., & Wyneken, J. (Eds.). 2002. *The Biology of Sea Turtles*. Vol. II. Boca Raton, FL: CRC Press: p. 472.

Manes, C., Pinton, D., Canestrelli, A., & Capua, I. 2022. Occurrence of fibropapillomatosis in green turtles (*Chelonia mydas*) in relation to environmental changes in coastal ecosystems in Texas and Florida: a retrospective study. *Animals*, 12(10), 1236. DOI: 10.3390/ani12101236.

Musick, J. A., & Limpus, C. J. 1997. Habitat utilization and migration in juvenile sea turtles. In: P. L. Lutz & J. A. Musick (Eds.), *The Biology of Sea Turtles*. pp. 137–163. Boca Raton, FL: CRC Press.

Ahead of print

Page-Karjian, A., Norton, T. M., Krimer, P., Groner, M., Nelson, S. E., & Gottdenker, N. L. 2014. Factors influencing survivorship of rehabilitating green sea turtles (*Chelonia mydas*) with fibropapillomatosis. *Journal of Zoo and Wildlife Medicine*, 45(3), 507–519. DOI: 10.1638/2013-0132R1.1.

Page-Karjian, A., Norton, T. M., Ritchie, B., Brown, C., Mancia, C., Jackwood, M., & Gottdenker, N. L. 2015. Quantifying Chelonid herpesvirus 5 in symptomatic and asymptomatic rehabilitating green sea turtles. *Endangered Species Research*, 28(2), 135–146. DOI: 10.3354/esr00687.

Patrício, A. R., Herbst, L. H., Duarte, A., Velez-Zuazo, X., Santos Loureiro, N., Pereira, N., Tavares, L., Santos, M. R., Soares, A. M. V. M., & Cabral, H. N. 2012. Global phylogeography and evolution of chelonid fibropapilloma-associated herpesvirus. *Journal of General Virology*, 93(5), 1035–1045. DOI: 10.1099/vir.0.038950-0.

Quackenbush, S. L., Work, T. M., Balazs, G. H., Casey, R. N., Rovnak, J., Chaves, A., duToit, L., Baines, J. D., Parrish, C. R., Bowser, P. R., & Casey, J. W. 1998. Three closely related herpesviruses are associated with fibropapillomatosis in marine turtles. *Virology*, 246(2), 392–399. DOI: 10.1006/viro.1998.9207.

R Core Team. 2023. *R: A language and environment for statistical computing*. Vienna: R Foundation for Statistical Computing.

Rossi, S., Sánchez-Sarmiento, A. M., Vanstreels, R. E. T., dos Santos, R. G., Prioste, F. E. S., Gattamorta, M. A., Grisi-Filho, J. H. H., & Matushima, E. R. 2016. Challenges in evaluating the severity of fibropapillomatosis: a proposal for objective index and score system for green sea turtles (*Chelonia mydas*) in Brazil. *PLoS ONE*, 11(12), e0167632. DOI: 10.1371/journal.pone.0167632.

Ahead of print

Silva, I. S. 2019. Detection of Chelonid alphaherpesvirus-5 (ChHV5) in blood and organs of *Chelonia mydas* (Testudines, Cheloniidae) and correlation with morphometrics in animals with and without fibropapillomatosis in the coast of Ubatuba/São Paulo. Master dissertation. Faculty of Veterinary Medicine and Animal Science, University of São Paulo, São Paulo, Brazil. p. 117.

Tamura, K., Stecher, G., & Kumar, S. 2021. MEGA11: Molecular Evolutionary Genetics Analysis version 11. *Molecular Biology and Evolution*, 38(7), 3022–3027. DOI: 10.1093/molbev/msab120.

The jamovi project. 2025. *jamovi* (Version 2.7) [Computer Software].

Torezani, E., Baptistotte, C., Mendes, S. L., & Barata, P. C. R. 2010. Juvenile green turtles (*Chelonia mydas*) in the effluent discharge channel of a steel plant, Espírito Santo, Brazil, 2000–2006. *Journal of the Marine Biological Association of the United Kingdom*, 90(2), 233–246. DOI: 10.1017/S0025315409990579.

Vanstreels, R. E. T., Durant, A., Santos, A. P., Santos, R. G., Sarmiento, A. M. S., Rossi, S., Setim, F. E., Gattamorta, M. A., Matushima, E. R., Mayorga, L. F. S. P., & Uhart, M. M. 2023. Exploring the relationship between environmental drivers and the manifestation of fibropapillomatosis in green turtles (*Chelonia mydas*) in eastern Brazil. PLoS ONE, 18(8), e0290312. DOI: 10.1371/journal.pone.0290312.

Work, T. M., & Balazs, G. H. 1999. Relating tumor score to hematology in green turtles with fibropapillomatosis in Hawaii. *Journal of Wildlife Diseases*, 35(4), 804–807. DOI: 10.7589/0090-3558-35.4.804.

Submitted: 13 April 2026

Accepted: 23 October 2026

Ahead of print

Oecologia Australis (ISSN: 2177-6199)
Ahead of print (https://revistas.ufrj.br/index.php/oa/issue/view/1109/showToc)
Article ID: AO#73365
Published online: 07 NOVEMBER 2026

Published online: 07 Novermber 2026

Associate Editor: Drª Rosana Gentile

Ahead of print