

# TARSAL TUNNEL SYNDROME: A STILL CHALLENGE CONDITION

## SÍNDROME DO TÚNEL DO TARSO: UMA CONDIÇÃO AINDA DESAFIADORA

Celmir de Oliveira Vilaça<sup>1,2</sup>, Bruno Pessoa<sup>3</sup>, Janaína de Moraes Silva<sup>4</sup>, Victor Hugo Bastos<sup>5</sup>, Diandra Martins<sup>5</sup>, Silmar Teixeira<sup>6</sup>, Victor Marinho<sup>6</sup>, Rossano Fiorelli<sup>7</sup>, Vanessa de Albuquerque Dinod<sup>8</sup>; Marco Orsini<sup>7,9</sup>

### ABSTRACT

Tarsal tunnel syndrome is a rare, under diagnosed and often confused neuropathy with other clinical entities. There is a lack of population studies on this disease. Herein, we performed a non-systematic review of articles between January 1992 and February 2018. Although with a less complex anatomy comparing to the carpal tunnel, the tarsal tunnel is source of pain and some other conditions. Treatment involves conservative measures such as analgesics and physical therapy rehabilitation or surgical procedures in case of conservative treatment failure. Randomized control studies are lack and mandatory for uncover the best modality of treatment for this condition.

**Keywords:** Tarsal Tunnel Syndrome, Tibial Neuropathy, Nerve Compression Syndromes

### RESUMO

A Síndrome do túnel do tarso é uma rara e subdiagnosticada neuropatia geralmente confundida com outras entidades clínicas. Há falta de estudos populacionais sobre a doença. Assim sendo, realizamos uma revisão da literatura de artigos entre Janeiro de 1992 e fevereiro de 2018. Apesar de possuir uma anatomia de menor complexidade comparada ao túnel do carpo, o túnel do tarso é origem de dor e algumas outras condições. O tratamento envolve medidas conservadoras como analgésicos e terapia de reabilitação ou procedimentos cirúrgicos, em caso de falha do tratamento conservador. Estudos randomizados são escassos e necessários para descoberta da melhor modalidade de tratamento desta condição.

**Palavras-chaves:** Síndrome do Túnel do Tarso, Neuropatia Tibial, Síndromes de Compressão Nervosa

<sup>1</sup>Institute of Traumatology and Orthopedics (INTO), Rio de Janeiro-RJ, Brazil.

<sup>2</sup>Federal Fluminense University (UFF); MMC / Division of Neurology; Postgraduate Program in Neurology / Neurosciences, UFF, Niterói-RJ, Brazil.

<sup>3</sup>Federal Fluminense University (UFF); Assistant professor, Division of Neurosurgery; Niterói-RJ, Brazil.

<sup>4</sup>State University of Piauí (UESPI); Assistant professor, Health Sciences Center; Teresina-PI, Brazil

<sup>5</sup>Federal University of Piauí (UFPI); Brain Mapping and Functionality Laboratory; Parnaíba-PI, Brazil.

<sup>6</sup>Federal University of Piauí (UFPI); Neuro-innovation Technology & Brain Mapping Laboratory; Parnaíba-PI, Brazil.

<sup>7</sup>University of Vassouras; Applied Science to Health Masters Program;

<sup>8</sup>Rio de Janeiro Federal University - Radiology Service - UFRJ - Brazil

<sup>9</sup>Federal University of Piauí (UFPI); Brain Mapping and Functionality Laboratory; Parnaíba-PI, Brazil.

**Endereço para correspondência:** Marco Antonio Orsini Neves. University of Vassouras, Brazil. Email: orsinimarco@hotmail.com. +5521980049832

## INTRODUCTION

Pain in the plantar and calcaneal region occurs in up to 15% of adult subjects. Among these causes Tarsal Tunnel Syndrome (TTS) is often an under diagnosed condition.<sup>1</sup> The first clinical description of TTS was in 1918 by Von Malisé.<sup>2</sup> Later, Pollock and Davis described the compression of the posterior tibial nerve by post-traumatic fibrous tissue in 1932.<sup>3</sup> Finally Keck and Lam in 1962 were the first to describe the tarsal tunnel syndrome as we know it nowadays.<sup>4,5,6</sup>

TTS can be defined as the compression of the tibial nerve or its branches in the ankle tarsal tunnel.<sup>7</sup> The tibial nerve corresponds to the greater division of the sciatic nerve and is derived from the ventral branches of the roots of L5, S1 and S2.<sup>8</sup> The TTS represents the most frequent cause of compressive foot neuropathy and the most frequent site of compression of the tibial nerve.<sup>9</sup> There is a predominance of females compared to males, but with a less pronounced difference compared to carpal tunnel syndrome (CTS).<sup>10</sup> It can affect people of varying ages, with cases from the second to ninth decade of life.<sup>11</sup> Some authors divide the tarsal tunnel syndrome into two types: anterior and posterior. The posterior one (TTSP) compromises with compression of the tibial nerve is used as a synonym of TTS by most specialists being the most frequently diagnosed and is the one addressed in this manuscript. Anterior tarsal tunnel syndrome (TTSA) indicates a less common form of compression affecting the deep fibular nerve in the ankle and will not be addressed here.<sup>12</sup> Unfortunately, no epidemiological studies address the prevalence and incidence of TTSP or simply TTS in the general population.<sup>9</sup> In electrophysiological studies, the rate of TTS is 0.4% to 0.5% of the total number of exams.<sup>10</sup> Patients with TTS may have an identifiable factor in up to 80% of the cases.<sup>13</sup> The causes of TTS can be divided into intrinsic or extrinsic injuries. Intrinsic ones are related to the presence of space-occupying lesions within the tarsal tunnel while the extrinsic lesions external to the canal.<sup>11</sup> The most common cause of TTS is the extrinsic compression of the tibial nerve due to trauma.<sup>2</sup> External compression may affect the vasa nervorum of the tibial nerve provoking ischemia with difficulty of the axonal transport. Compression above 40 mmHg is capable of causing axonal ischemia, and above 80 mmHg these lesions may become irreversible.<sup>14</sup>

The discussion herein about TTS becomes relevant due to its challenging diagnosis, being often confused with other more frequent states of pain in the plantar re-

gion and the calcaneus. This mistake, in turn, may increase the risks of incorrect treatments associated with unnecessary tibial nerve decompression surgeries.

## METHODS AND RESULTS

We did a non-systematic review of articles on the Google Scholar and PubMed platform between January 1992 and February 2018. Papers in English with the title “Tunnel Tarsal Syndrome” in the title of the journal were preferred. We obtained a total of 434 articles addressing the theme. We have included trial articles, review articles, case reports or expert opinions without any specific criteria for disregarding them except to be written in English language. Some references were chosen from periodicals of the initial search. At the end, we used a total of 39 references to perform this review.

## DISCUSSION

### *Anatomy of the Tarsus Tunnel*

Anatomically the tarsal tunnel is a fibro-osseous space located in the medial area of the ankle (Figure 1). Laterally it is formed by the posterior wall of the talus, medial part of the talocalcaneal joint and medial wall of the calcaneus. Medially the tunnel is formed by the retinaculum of the flexors and its fibrous expansion to the tendon of the posterior tibial muscle and long abductor of the hallucis.<sup>15</sup> The tunica of the tarsus is located posterior and inferior to the medial malleolus and has the dimension of approximately 10 cm proximal of the medial malleolus.<sup>16</sup> Inwardly, a neurovascular component crosses the tarsal tunnel. This tunnel is composed of the tibial nerve, tendon of the posterior tibialis muscles, flexor digitorum of the fingers, long flexor of the hallucis, the posterior tibial artery and vein.<sup>4</sup> Unlike the carpal tunnel, the components of the tarsal tunnel are separated by a septum, making it more difficult to differentiate these structures.<sup>17</sup> On the other hand, the thickness of the flexor retinaculum is smaller in the tarsus tunnel when compared to the carpal tunnel making the dissection of the first easier during the surgical procedure.<sup>18</sup> This is one of the possible explanations of the frequency of the TTS be much smaller in comparison to CTS.<sup>19</sup> Another explanation for the greater occurrence of CTS in comparison to TTS would be the fact that in the first beyond the median nerve, there is the passage of nine tendons, all susceptible to the most diverse inflammatory

conditions. There are also a greater number of bones and joints in the carpus concerning the tarsus. Each of these joints is subject to the occurrence of displacements and synovitis with greater potential of compression of the median nerve in comparison to the tibial nerve.<sup>20</sup>

The tibial nerve in the tarsal tunnel is divided into three branches: lateral plantar, medial plantar and calcaneal.<sup>4</sup> More often, the calcaneal branch originates from the tibial nerve. However, it can also originate from its medial plantar branch.<sup>21</sup> Compression may occur either proximal in the tunnel, affecting the tibial nerve, or more distally, affecting only one or more of its branches.<sup>3</sup> Compression of the lateral plantar nerve is more frequent when compared to compression of the medial plantar one.<sup>1</sup> The separation of the tibial nerve in its medial branches and lateral approach occurs proximal to the flexor retinaculum in 5% of people. This proximal bifurcation may be another important factor for the occurrence of TTS, also explaining its low frequency in the general population compared to CTS.<sup>21</sup> Distal compression of the tibial nerve is often associated with diseases of the posterior tibialis tendon and chronic plantar fasciitis.<sup>20</sup>

cramps. The symptoms worsen with ambulation or standing upright for long periods. There may be a nocturnal worsening of symptoms.<sup>9</sup> Rarely, in chronic and advanced conditions, there is a loss of strength and atrophy of the foot muscles.<sup>4</sup> Some sports activities present a higher risk of TTS. Of note are sports activities where it is fundamental to use lower limbs as martial arts judo variants, running and jumping.<sup>22</sup>

During the anamnesis, the patient usually presents difficulty in pointing out exactly where the pain in the plantar region is located. At the clinical examination, there may be a presence of the Tinel's sign or irradiated pain during percussion of the nerve.<sup>14</sup> The presence of the Tinel's sign is associated with a better outcome of the surgical treatment and occurs in about 50% of the patients.<sup>23</sup> This sign possibly has origin in the firing of axon terminals (sprouting) in regeneration after injury by compression. In chronic processes, the lack of regenerating axons can lead to the disappearance of Tinel's sign and indicate a worse surgical outcome.<sup>14</sup>

Another sign sometimes observed in the clinical evaluation is the presence of irradiated pain also known as

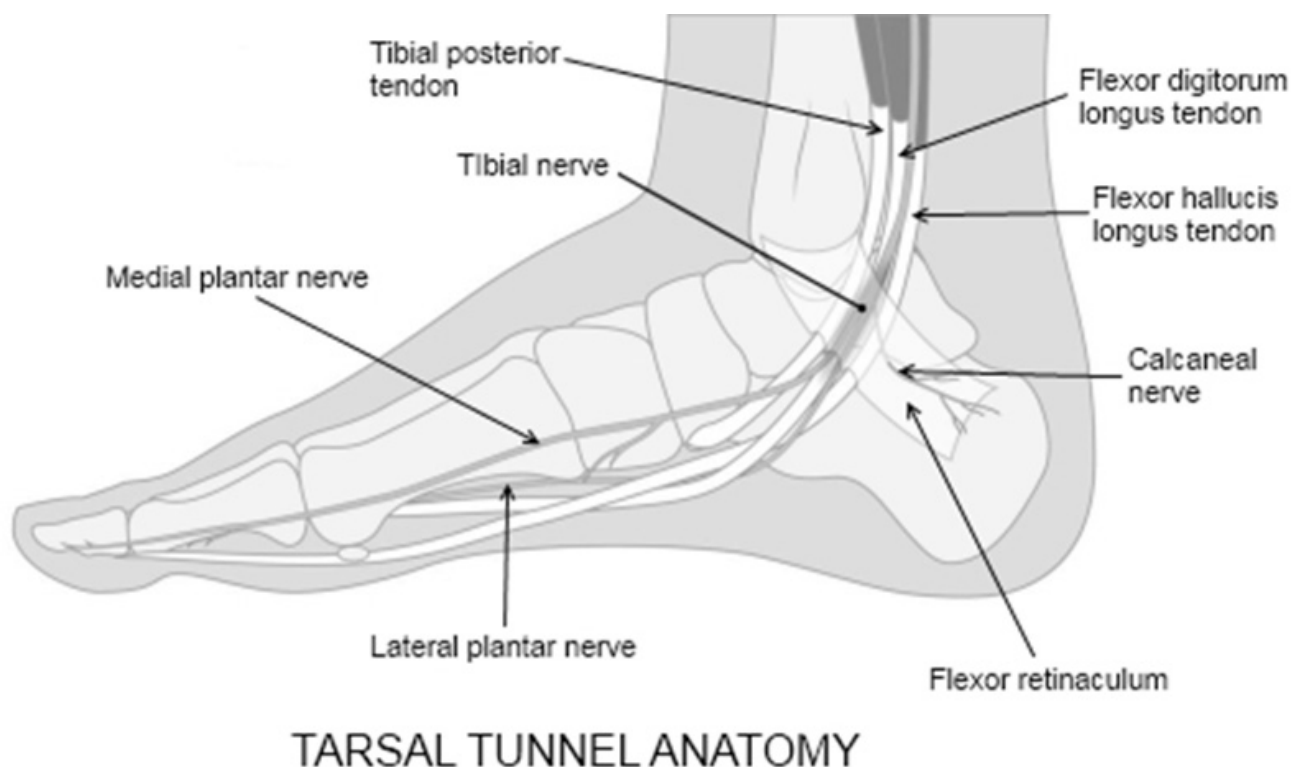


Figure 1: Tibial nerve compression in tarsal tunnel.  
Source: Own elaboration.

### Clinical evaluation

The most frequently reported symptoms are pain and numbness in the sole of foot, in addition to tingling or

Valleix phenomenon. In this case, there is pain and dysesthesia proximally and distally along the course of the nerve during compression posterior and inferior to the medial

malleolus, in the tarsal tunnel.<sup>16</sup> In some cases, the pain may ascend to the calf region.<sup>23</sup>

In the clinical evaluation of TTS, pain can also be evoked by dorsal flexion of the ankle in association with foot eversion for five to ten seconds. One may find this aspect due to variation in the size of the tarsal tunnel during movement. The tunnel volume is larger with the ankle in neutral compared to the everted or inverted position. It is equivalent to the Phalen test for carpal tunnel syndrome in the upper limbs.<sup>24</sup> Decreased sensation in the areas of the medial and lateral plantar nerve is the most common sign.<sup>25</sup>

Another TTS evaluation test is the so-called triple-stress test. In this test, the tibial nerve is compressed behind the medial malleolus for 30 seconds in conjunction with plantar flexion and foot inversion causing symptoms of pain and numbness.<sup>26</sup> Sometimes compression of the tibial nerve occurs due to intrinsic tunnel injury due to vessel compression varicose veins. In this case, we can perform the Turks test, which is based on the application of a tourniquet above the medial malleolus between systolic and diastolic pressures reproducing the symptoms.<sup>2</sup> Finally, Gerow suggests performing the modified Bragard test.<sup>27</sup> In this case, unlike the initial description, we did not perform the elevation of the extended leg, and even then the symptoms of TTS were triggered.<sup>12,27</sup> Once one diagnoses TTS, we could assess the severity of the condition using the Takakura scale based in clinical aspects of syndrome with a total score of 10 points representing a normal foot. This scale is also used to evaluate the surgical results: (Table 1).<sup>22,28</sup>

Table 1: The rating scale for the severity of tarsal tunnel syndrome and surgical outcome from Takakura 1991<sup>28</sup>

SYMPTOM	ABSENT	SOME	DEFINITE
PAIN, SPONTANEOUS OR ON MOVEMENT	0	1	2
BURNING PAIN	0	1	2
TINEL SIGN	0	1	2
SENSORY DISTURBANCE	0	1	2
MUSCLE ATROPHY OR WEAKNESS	0	1	2

Normal foot or excellent surgical outcome scores 10 points. Good surgical results: 8 or 9 points. Fair results: 6 or 7 points. Bad result: five or below  
Source: Takakura et al, 1991.

### Complimentary evaluation

Radiographic examination (RX) of the ankle is the method of choice for initially evaluating TTS and it assesses the existence of alterations of the bony structure of the components of the tarsus tunnel. It may also show the presence of fractures, osteophytes and predisposing factors for tibial nerve compression as varus or valgus foot

deformities.<sup>29</sup>

Ultrasound examination (US) is important in cases of space occupying lesions within the tarsal tunnel, mainly when this lesion is made of soft tissues. Also, it may aid in the discovery of minor lesions not observed during magnetic resonance imaging (MRI).<sup>17</sup>

The MRI shows accuracy for lesions occupying space in the tarsal tunnel around 80%.<sup>29</sup> Among the space occupying lesions in the tarsal tunnel, the most frequent is the presence of a ganglion. This ganglion may be of articular or tendinous origin in the ankle.<sup>3</sup> Others estimate the presence of varicosities to be the intrinsic lesion of the most frequent channel.<sup>21</sup>

The electrophysiological examination through electroneuromyography (ENMG) is considered the gold standard for TTS, although there is no correlation between the electromyography findings and the success of the surgical treatment.<sup>2</sup> It may be useful in supporting the clinical diagnosis and in the search for differential diagnoses in 80% of the cases.<sup>30</sup> A comparative study between the two limbs should always be performed using ENMG, since the number of abnormal findings may rise the suspicion of TTS in asymptomatic individuals.<sup>12</sup> In these cases, electromyography in the abductor hallucis and fifth finger usually indicate changes causing false positive diagnosis.<sup>29</sup>

ENMG also assists in the detection of isolated lesions of the lateral and medial plantar nerves divisions as they enter their respective tunnels distally to the tarsal tunnel.<sup>12</sup> Prolongation of the distal motor latencies of the abductor hallucis muscle suggests lesion of the medial plantar branch and the fifth finger of the lateral plan-

tar nerve. Sensory conduction studies are more sensitive compared to motor conduction studies for the diagnosis of TTS, although its specificity is lower than motor conduction studies. Some investigators do not recommend the use of ENMG in the evaluation of TTS despite its unequivocal utility because of the lack of standardized results for comparison.<sup>9</sup> Besides others report the difficulties of

assessment of sensory conduction in TTS, in theory due to the callosities, edema and structural deformities in the foot of some individuals.<sup>29</sup> Lastly, the presence of unchanged ENMG examination in a patient with a history and a compatible physical examination does not rule out the diagnosis of TTS.<sup>21</sup>

### *Differential diagnosis*

The determination of TTS involves a triad formed by three elements: 1 - the presence of consistent clinical symptoms; 2- Tinel's sign presence; 3- Positivity of nerve conduction tests. If two of these findings are present, the diagnosis is likely. The lack of the three results excludes the diagnosis.<sup>31</sup> Diagnostic errors of TTS can reach up to 75% of cases in some series and TTS has a lower association with systemic diseases when compared to CTS.<sup>8,10</sup> Differently from other differential diagnoses, it should be borne in mind that TTS is generally unilateral, with rare bilateral cases.<sup>7</sup>

Even more exceptional are the examples of association between carpal tunnel syndrome and tarsal tunnel syndrome in the same individual.<sup>32</sup>

A diagnosis commonly mistaken for TTS is plantar fasciitis. This condition corresponds to the leading cause of pain in the plantar region, encompassing the area of the calcaneus.<sup>1</sup> Represents an enthesopathy for the first steps in the morning or after a prolonged stay at rest. This condition is self-limited and usually improves with ambulation. Thus, TTS may be mainly confused with calcaneal spur when there is heel pain related to compression of the calcaneal branch of the nerve.<sup>12</sup> The spur in these cases can easily be identified through radiographic examinations.<sup>23</sup>

Another more frequent differential diagnosis in comparison to TTS is the presence of lumbar radiculopathy or polyneuropathies associated with systemic diseases such as diabetes.<sup>16</sup> In athletes, fibular neuropathies and radiculopathies of the lower limbs are not common when compared to the upper limbs. In these cases, they may be confused with TTS in athletes with increased use of the legs.<sup>22</sup> Also, there is the possibility of "Double Crush Syndrome" in the lower limbs. This would represent the association of lumbar radiculopathy and TTS in a way analogous to that found in carpal tunnel syndrome associated with cervical root injury.<sup>19</sup> These associations increase the importance of conducting nerve conduction studies during the evaluation of TTS even in clinically well defined. Other researchers indicate difficulty in determining the presence

of TTS in cases of associated diabetes.<sup>14</sup>

### *Treatment*

TTS treatment may be either conservative or surgical. Unfortunately, there are no randomized trials evaluating the best treatment for TTS.<sup>33</sup>

Non-surgical or conservative treatment involves the use of non-steroidal anti-inflammatory drugs (NSAIDs), immobilization, local ice application, corticosteroid infiltration, and bracing. In athletes, conservative treatment usually is enough in cases of dynamic or flexible compression. In this regard, NSAIDs (non-steroidal anti-inflammatory) is useful in cases of tenosynovitis due to compression of the canal components. Treatment with corticosteroid, although effective should be used with restrictions because of the possibility of intravascular injection or tendinous rupture in the tarsal tunnel.<sup>24</sup> Medications for neuropathic pain such as gabapentin, may be attempted to relieve symptoms in selected cases.<sup>31</sup>

Persistent symptoms for more than six months, failure of non-surgical treatment or presence of space occupying lesions within the canal indicate a need for surgery.<sup>11</sup> The presence of severe pain already at the beginning of the condition may also mean a failure in conservative treatment and surgery is recommended from the beginning.<sup>34</sup> Some authors indicate the surgical procedure when the ENMG shows changes of two standard deviations far from the expected result in the controls.<sup>3</sup> Surgical treatment success rates range depending on the series and manner of selection of the indices.<sup>24</sup> Patients with no changes or deformities in the ankle joint as well as weight reduction prior to surgery have a better surgical prognosis.<sup>34</sup>

In addition to the cavus or varus foot where there is an alteration of the volume of the tarsal tunnel favoring the compression of the tibial nerve, there are cases of tarsal coalition. The tarsal coalition is the name given to the presence of bone, fibrous or fibro cartilaginous union of one or more tarsal bones. The most frequent subtype is the talocalcaneal coalition favoring the appearance of TTS.<sup>35</sup>

The failure of the surgical treatment has varying frequencies, ranging from 5 to 50% depending on the series studied.<sup>35,36</sup> Failures in surgical treatment are usually associated with lack of correct nerve release, bleeding with scarring in the tarsal tunnel, direct damage to the tibial nerve and its branches during surgery. Still, the hypersensitivity due to the chronicity of the process may figure as a cause of failure of the surgical procedure itself. In cases of

symptomatic chronicity, their existence for more than one year is a factor of poor surgical prognosis.<sup>29</sup> The presence of systemic disease or neuropathies such as diabetes is also cited as a cause of surgical failure.<sup>36,37</sup> Post rehabilitation may require an estimated timeframe of up to 24 weeks.<sup>23</sup> On the other hand, some specialists contraindicate the surgical treatment when they expect a poor prognosis in any given situation.<sup>38,39</sup> The primary neurological complications of decompression refer to the loss of sensation in the plantar region and the occurrence of cases of complex regional pain.<sup>23</sup> However, there is a consensus among specialists about the need for conservative treatment before the surgical procedure in most cases.<sup>25</sup>

## CONCLUSION

TTS is still a rare and often misdiagnosed condition. There are many differences between TTS and its analog in the upper limbs, CTS. There is a shortage of epidemiological studies on TTS as well as standardized electrophysiological studies for its diagnostic evaluation. Importantly, there are no randomized studies evaluating the best treatment, whether conservative or surgical. We should be attentive to the diagnosis of TTS in all patients who present pain and numbness in the plantar region, especially patients with deformities in the feet. Given its importance, randomized control studies are mandatory addressing prognosis factors as well as the best modalities of treatment of this condition.

## CONFLICT OF INTEREST

The authors declare that there is no conflict of interest.

## REFERENCES:

- Alshami AM, Souvlis T, Coppieters MW. A review of plantar heel pain of neural origin: Differential diagnosis and management. *Man. Ther.* 2008;13(2):103-11.
- Prado M De, Cuervas-Mons M, Golanó P, Rabat E, Vaquero J. The tarsal tunnel syndrome. *Fuss und Sprunggelenk.* 2015;13(4):227-36.
- Cancilleri F, Ippolito M, Amato C, Denaro V. Tarsal tunnel syndrome: Four uncommon cases. *Foot Ankle Surg.* 2007;13(4):214-7.
- Keck C. The tarsal-tunnel syndrome. *J Bone Joint Surg.* 1962;44(1):180-2.
- Lam SJS. A tarsal-tunnel Syndrome. *Lancet.* 1962; 2:1354-55.
- Ozdemir O, Calisaneller T, Sonmez E, Altinors N. Tarsal tunnel syndrome in a patient on long-term peritoneal dialysis: case report. *Turk. Neurosurg.* 2007;17(4):283-5.
- Paolasso I, Granata G, Erra C, Coraci D, Padua L. Bilateral tarsal tunnel syndrome related to intense cycling activity: proposal of a multimodal diagnostic approach. *Neurol. Sci.* 2015;36(10):1921-3.
- Oh SJ, Meyer RD. Entrapment neuropathies of the tibial (posterior tibial) nerve. *Neurol. Clin.* 1999;17(3):593-615.
- Patel AT, Gaines K, Malamut R, Park T a, Toro DR Del, Holland N. Usefulness of electrodiagnostic techniques in the evaluation of suspected tarsal tunnel syndrome: an evidence-based review. *Muscle Nerve.* 2005;32(2):236-40.
- Mondelli M, Morana P, Padua L. An electrophysiological severity scale in tarsal tunnel syndrome. *Acta Neurol. Scand.* 2004;109(4):284-9.
- Llanos LF, Vila J, Nunez-Samper M. Clinical symptoms and treatment of the foot and ankle nerve entrapment syndromes. *Foot Ankle Surg.* 1999;5:211-8.
- Beneliyahu D. Tarsal tunnel syndrome. *Dyn. Chiropr.* 1994;12(26):1-3.
- Singh G, Kumar VP. Neuroanatomical basis for the tarsal tunnel syndrome. *Foot ankle Int.* 2012;33(6):513-8.
- Dellon AL. The Four Medial Ankle Tunnels: A Critical Review of Perceptions of Tarsal Tunnel Syndrome and Neuropathy. *Neurosurg. Clin. N. Am.* 2008;19(4):629-48.
- Choufani E, Gavanier B, Gross JB, Belleville R, Barla M, Mainard D. Tarsal Tunnel Syndrome: Does Etiology Matter? *Med. Chir. du Pied.* 2016;32(3):72-6.
- Williams THD, Robinson AHN. Entrapment neuropathies of the foot and ankle. *Orthop. Trauma.* 2009;23(6):404-11.
- Nagaoka M, Matsuzaki H. Ultrasonography in Tarsal Tunnel Syndrome. *J Ultrasound Med.* 2005;24(8):1035-40.
- Kohno M, Takahashi H, Segawa H, Sano K. Neurovascular decompression for idiopathic tarsal tunnel syndrome: Technical note. *J. Neurol. Neurosurg. Psychiatry.* 2000;69(1):87-90.
- Zheng C, Zhu Y, Jiang J, Ma X, Lu F, Jin X, et al. The prevalence of tarsal tunnel syndrome in patients with lumbosacral radiculopathy. *Eur. Spine J.* 2016;25(3):895-905.
- Gould JS. Tarsal Tunnel Syndrome. *Foot Ankle Clin.* 2011;16(2):275-86.
- Lau JTC, Daniels TR. Tarsal Tunnel Syndrome: A Review of the Literature. *Foot Ankle Int.* 1999;20(3):201-9.
- Kinoshita M, Okuda R, Yasuda T, Abe M. Tarsal tunnel syndrome in athletes. *Am. J. Sports Med.* 2006;34(8):1307-12.
- McSweeney SC, Cichero M. Tarsal tunnel syndrome-A narrative literature review. *Foot.* 2015;25(4):244-50.
- Doneddu PE, Coraci D, Loreti C, Piccinini G, Padua L. Tarsal tunnel syndrome: still more opinions than evidence. Status of the art. *Neurol. Sci.* 2017;38(10):1735-39.
- Kavlak Y, Uygur F. Effects of nerve mobilization exercise as an adjunct to the conservative treatment for patients with tarsal tunnel syndrome. *J. Manipulative Physiol. Ther.* 2011;34(7):441-8.
- Abouelela AAKH, Zohiery AK. The triple compression stress test for diagnosis of tarsal tunnel syndrome. *Foot.* 2012;22(3):146-9.
- Gerow G. Musculoskeletal System. In: Lawrence DJ. *Fundamentals of Chiropractic Diagnosis and Management.* Baltimore: William & Wilkins; 1991. p367-9.
- Takakura Y, Kitada C, Sugimoto K, Tanaka Y, Tamai S. Tarsal tunnel syndrome. Causes and results of operative treatment. *J. Bone Jt. Surgery, Br.* 1991;73(1):125-8.
- Ahmad M, Tsang K, Mackenney PJ, Adedapo AO. Tarsal tunnel syndrome: A literature review. *Foot Ankle Surg.* 2012;18(3):149-52.
- Lee MF, Chan PT, Chau LF, Yu KS. Tarsal tunnel syndrome caused by talocalcaneal coalition. *Clin. Imaging.* 2002;26(2):140-3.
- Hilario HC. Tarsal Tunnel Syndrome. In: Eltorai A, Ebersson C, Daniels A. *Orthopedic Surgery Clerkship: A Quick Reference Guide for Senior Medical Students.* Sham:Springer International Publishing; 2017. p423-5.
- Yurdal S., Aydinler K., Gökhan AA. Bilateral Carpal and Tarsal Tunnel Syndrome in The Same Patient: A Case Report. *J. Neurol. Sci. [Turkish].* 2008;25(2):167-70.
- McSweeney SC, Cichero M. Tarsal Tunnel Syndrome – a narrative review of the literature. *J. Foot Ankle Res.* 2015;8(Suppl 2):9.
- Gondring WH, Trepman E, Shields B. Tarsal tunnel syndrome: Assessment of treatment outcome with an anatomic pain intensity scale. *Foot Ankle Surg.* 2009;15(3):133-8.
- Guner B, Kose O, Turan A, Acar B, May H. Tarsal Tunnel Syndrome Due to Talocalcaneal Tarsal Coalition: A Case Report. *SMJ. Orthop.* 2016;2(3):1038-40.
- Gould JS. The Failed Tarsal Tunnel Release. *Foot Ankle Clin.* 2011;16(2):287-93.
- Gould JS. Recurrent tarsal tunnel syndrome. *Foot Ankle Clin.* 2014;19(3):451-67.
- Jerosch J, Schunck J, Khoja A. Results of surgical treatment of tarsal tunnel syndrome. *Foot Ankle Surg* 2006;12(4):205-8.
- Pfeiffer WH, Cracchiolo A. Clinical results after tarsal tunnel decompression. *J Bone Joint Surg* 1994;76(8):1222-30.