

# Traumatic arteriovenous fistula associated to pseudoaneurysm of the superficial temporal artery in a child – Case report and literature review

## *Fístula arteriovenosa traumática associada a pseudoaneurisma da artéria temporal superficial em uma criança – Relato de caso e revisão da literatura*

José Fernando Guedes-Corrêa<sup>1</sup>, Ana Caroline Siquara-de-Sousa<sup>2</sup>, Rogério Martins Pires de Amorim<sup>1</sup>, Lucas Loiola Santos<sup>1</sup>, Maristella Reis da Costa Pereira<sup>1</sup>

### RESUMO

As fístulas arteriovenosas (FAVs) e os pseudoaneurismas traumáticos extracranianos são malformações incomuns e, em sua maioria, estão associadas a traumatismo craniano fechado com lesão contusa de forte intensidade. O diagnóstico em geral é clínico, porém o exame de escolha para o diagnóstico definitivo é a angiografia. Nos casos em que a lesão é pequena, é possível abordá-la com embolização via endovascular com sucesso. A excisão cirúrgica, no entanto, ainda é o método de escolha para o tratamento. É relatado um caso de um paciente do sexo masculino, com 9 anos de idade, diagnosticado com FAV, acometendo o ramo frontal da artéria temporal superficial, secundária a trauma craniano contundente ocorrido três anos antes do diagnóstico.

**Palavras-chave:** Fístula arteriovenosa, falso aneurisma, traumatismos cranianos fechados, artérias temporais, infância.

### ABSTRACT

The arteriovenous fistulae (AVFs) and the extracranial traumatic pseudoaneurysms are uncommon malformations and in the majority of the cases are associated to closed head trauma with high intensity blunt lesion. The diagnosis is generally clinical, though the exam of choice for definitive diagnosis is an angiography. In minor lesion cases it's possible to successfully approach it with endovascular embolization. The surgical excision though, is the method of choice for the treatment. Here is reported a case of a 9-year-old male patient, diagnosed with AVF involving the frontal branch of the superficial temporal artery, secondary to blunt head trauma occurred three years before diagnosis.

**Keywords:** Arteriovenous fistula, pseudoaneurysm, head injuries, closed, temporal arteries, infancy.

<sup>1</sup> Neurosurgery Division, Hospital Universitário Gaffrée e Guinle, Universidade Federal do Estado do Rio de Janeiro (Unirio), Rio de Janeiro, RJ, Brazil.

<sup>2</sup> Department of Pathology, Hospital Universitário Gaffrée e Guinle, Unirio, Rio de Janeiro, RJ, Brazil.

**Address for correspondence:** Dra. Ana Caroline Siquara de Sousa. E-mail: anasiqara@gmail.com

## INTRODUCTION

Arteriovenous fistulas (AVFs) are vascular lesions characterized by communication between an artery and a vein, without capillary circulation intermediating those vessels. They are also described in the literature as “cirroid aneurysms” due to its resemblance to varicose veins (from the Greek “*kirsos*”).<sup>1</sup> The AVF may have multiple etiologies, being grouped in congenital and acquired. The acquired lesions are usually due to trauma (accidents, assaults or postoperative recovery), and involve most frequently the extremities, as also the trunk, the cranium and the face.<sup>2-5</sup> When originated from a trauma, more than just the formation of an AVF, the organization of hematomas may lead to the development of a pseudoaneurysm of the artery that irrigates the fistula. The period between the triggering factor, the formation of the AVF and the development of symptoms is highly variable, being possible to emerge in a few days, or take years to be detected.<sup>6,7</sup>

The AVFs and the extracranial traumatic pseudoaneurysms, in particular those of the superficial temporal artery (STA), are uncommon malformations, and in the majority of the cases are associated to closed head trauma with high intensity blunt wound.<sup>2,3,5,7-9</sup> Other causes described in literature are: penetrating wound to the scalp, fragments from exploding devices, capillary implant, temporomandibular arthroscopy, external ventricular derivation, post craniotomy with pterional access, and post cranial fixation with Mayfield headrest.<sup>2,3,5-7,10-12</sup>

Illustrating the rarity of such lesions, Rich *et al.*<sup>12</sup> analyzed data from 7,500 vascular trauma records in a military medical center and identified 262 AVFs (3.5% cases), which head and neck lesions were as follows: six common carotid AVFs, two internal carotid AVFs, two external carotid AVFs, and six vertebral AVFs, in a total of 16 reports (6.1% of all AVFs). In the civilian experience, Bole *et al.*<sup>9</sup> reviewing 23 cases of traumatic pseudoaneurysms in 23 patients, found four concomitant AVFs (17.4%), and none were in head and neck areas: one patient had AVF in hepatic artery, two in iliac artery and one in deep femoral artery.

The diagnosis of AVF associated to pseudoaneurysm of the STA is generally clinical, as the lesion, in most cases, presents itself as a pulsating tumor with fremitus and murmur that stops to digital compression of the proximal segment of the STA. If the mass

is non-pulsating, the differential diagnosis must be done with hematomas, soft tissue tumors, neuromas, foreign body granulomas, lipomas, sebaceous cysts, epidermis abscesses, and cysts.<sup>7,8</sup> Complementary exams may be performed, such as ultrasonography (US) with Doppler and contrast-enhanced computed tomography (CT), though the exam of choice for definitive diagnosis is angiography.

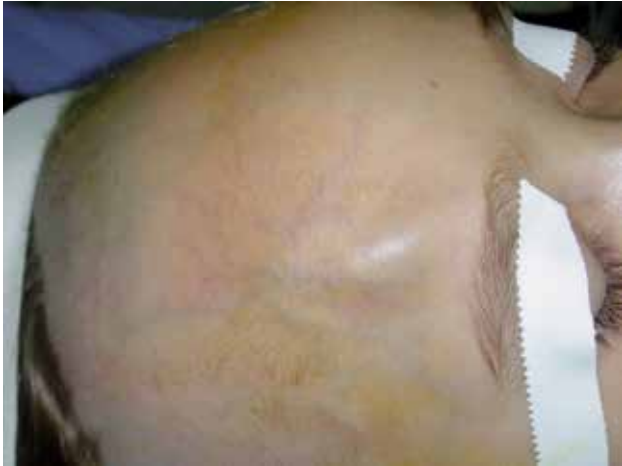The surgical excision is the method of choice for treatment of AVF of the STA associated to pseudoaneurysm and is indicated in view of the risk of bleeding, for pain relief, risk of facial nerve damage, and esthetical issues.<sup>2,7,8,13</sup> The surgery comprises in proximal and distal ligation of the STA and resection of both the fistula and the pseudoaneurysm. In minor lesion it's possible to approach them by endovascular embolization or by percutaneous sclerosing substances shot, although, these therapeutic options do not relieve the mass effect caused by the lesion.<sup>1,2,6,8,14,15</sup>

We describe as follows, a case of a child in school age presenting with a post traumatic AVF with formation of pseudoaneurysm of the frontal branch of the STA with three years of growth. The patient's parents signed an informed consent authorizing the publication of the case.

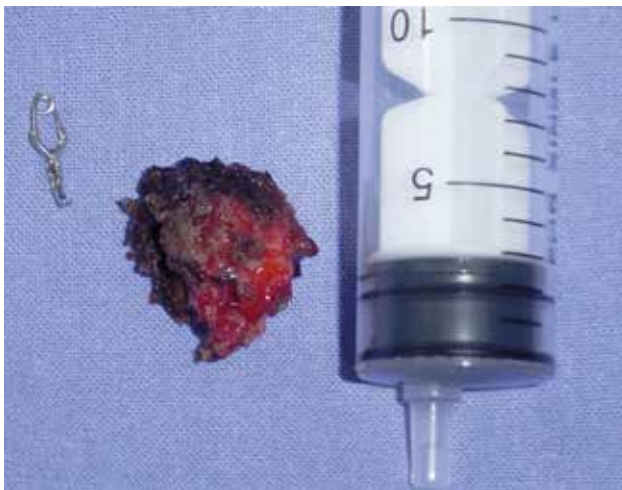
## CASE REPORT

A 9-year-old male patient suffered a blunt trauma to the right frontal region when he collided with another child during a soccer match three years before. In the following years the progressive growing of a tumor in the topography of the trauma was noticed (Figure 1).

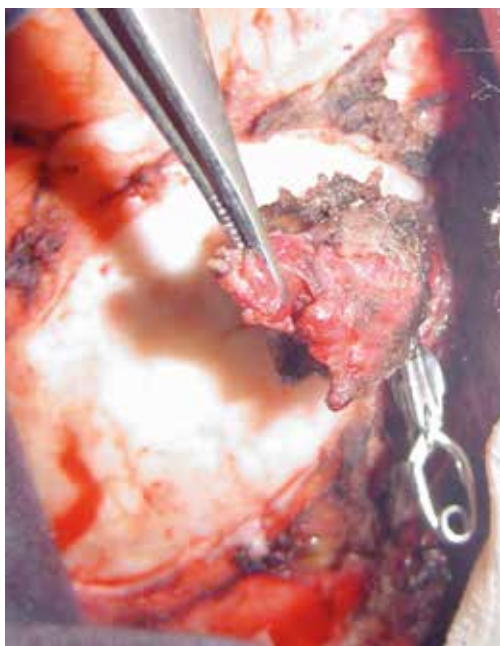
The palpation of the lesion showed a painful pulsating mass, with fremitus, sizing 4.0 x 3.0 cm. The definitive diagnosis of post traumatic AVF of the frontal branch of the STA was made with US Doppler that showed a subcutaneous vascular lesion in the frontal region, with high frequency blood flow and dilatation of the intraorbital and scalp veins. The patient was also submitted to a CT that showed bone remodeling of the region adjacent to the lesion. The patient was operated for correction of the AVF. After full exposure of the lesion evidencing its proximal and the distal branches, the frontal branch of the STA pseudoaneurysm was clipped, followed by complete removal of the fistula (Figures 2 and 3).



**Figure 1.** Nine year-old patient with a pulsating mass on forehead.

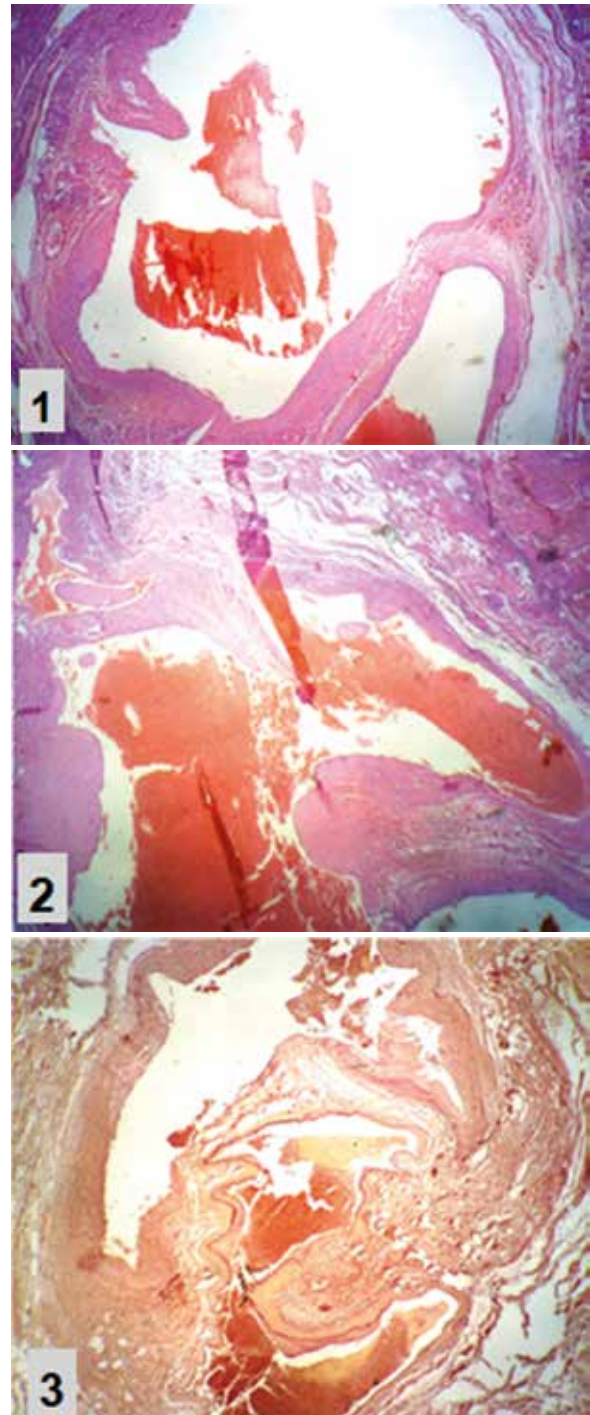


**Figure 2.** Surgical image of frontal branch of the STA pseudoaneurysm clipped.



**Figure 3.** Surgical specimen of the STA pseudoaneurysm.

No postoperative complications were recorded, the patient being discharged two days after the surgery, without symptoms at the time. The histopathological exam of the lesion was compatible with diagnosis of AVF (Figure 4).



**Figure 4.** (1) Histological sections showing superficial temporal artery and vein (H&E staining, 4x); (2) Histological sections showing superficial temporal artery and vein forming arteriovenous fistula (H&E staining, 4x); (3) Histological sections showing the right superficial temporal artery and vein (elastic fiber special stain, 4x).

## DISCUSSION

Arteriovenous malformations associated to pseudoaneurysms of the superficial temporal artery are rare complications of lesions on the scalp. In general, when due to blunt head trauma, they occur in regions where the STA crosses bone salient structures like the zygomatic arch, or the insertion of the temporal muscle fascia on the superior temporal line, where the anterior branch of the STA locates directly on the periosteum.<sup>2,3,5,7,8</sup> Also, due to iatrogenic causes, they can be found in the local of the incision on the scalp after the craniotomy, and other surgical procedures.

The pathogenesis of the traumatic AVFs is not yet fully disclosed. A lesion is characterized by multiple endothelial channels between the arterial and the venous systems. Marks *et al.*<sup>16</sup> suggest that the rupture of the *vasa vasorum* of the artery and the vein in the trauma region, with subsequent formation of hematomas lead to the development of endothelial buds that proliferate and create countless vascular channels connecting both systems, originating the AVF.<sup>2,3,16</sup> After some time, the organization of the hematoma creates a capsule wall constituted of fibrotic tissue and the reabsorption of cloths in its interior leads to formation of a lumen, generating the pseudoaneurysm, as described initially by Manz and Gomes in a case report of traumatic pseudoaneurysm of STA related to sport activity.<sup>17</sup> Moran *et al.*<sup>3</sup> mention a laceration mechanism, in which simultaneous lacerations of the artery and the close vein form a fistula.

Another phenomena related to the AVF is the dilatation of the artery that irrigates it. If the fistula remains for several years, the increase of blood flow may lead to irreversible degenerative changes of the arterial wall with fracture of the elastic fibers, atrophy of the smooth muscle cells of the middle tunic and decrease of the elastic tissue, making the structure thin and friable. Thus, the late development of the aneurysm may occur in a proximal area to the AVF even after its ligation.<sup>18</sup>

The AVFs may have multiple clinical presentations varying from an asymptomatic deformity that causes aesthetic discomfort to even a large volume tumor, pulsating, with fremitus and murmur of systolic enhancement, the patient complaining of

local pain, clinks, headache and dizziness.<sup>2-4</sup> Generally, the patient himself relates the occurrence of the symptoms with a history of trauma in the local of the lesion, weeks or months before, compatible date with the present case, in which the family made reference to the trauma occurring three years before the diagnosis. When strongly suggestive characteristics of vascular lesion occur, such as pulsating mass and fremitus, the diagnosis is basically clinical, and complementary exams may be ordered with the purpose of elucidating the anatomy of the lesion, and its relation with adjacent structures. However, when the mass is not of a pulsating kind, the differential diagnosis with sebaceous adenomas, neurofibromas, lipomas, cysts, abscesses, soft tissue tumors, among other skin lesions, should be done, and the mass properly analyzed. Such variability in the clinical expression of the lesion and the diversity of differential diagnosis may take the patient through several specialists before having the definitive diagnosis.

Image exams are of great value to study the lesion and surgical planning, especially if the endovascular treatment is considered. The standard exam to evaluation and diagnosis of the AVF and the pseudoaneurysm of STA is the selective angiography of the external carotid system.<sup>2,14,19-21</sup> The US with Doppler is a non-invasive exam that should be considered as contributory for the diagnoses by establishing the vascular origin of the lesion with high speed flow.<sup>7,21</sup> The contrast enhanced CT, then, will show an isodense expansion that shows homogeneous enhancement in its interior after the infusion of contrast, and organized cloths forming its capsule.<sup>6-8,21</sup> The arteriography by MRI has also being used for providing detailed images of the fistula anatomy<sup>14,19,21,22</sup>.

The choice of surgical treatment of the lesion instead of a conservative treatment is justified due to the risk of bleeding, even if the lesion is small,<sup>13</sup> to relieve the symptoms such as pain, clinking and headache, due to the risk of facial nerve damage, and for aesthetic reasons.<sup>5,7,8,13,14,19,21,22</sup>

Different options of treatment of the AVF and the pseudoaneurysm are described in the literature, such as ligation of the vessels, surgical excision, transvenous and transarterial embolization, and percutaneous injection of sclerosing substances. The ligation of vessels that irrigate the fistula proved

inefficient due to great recurrence, considering that collateral small vessels that irrigate lesion increase, reopening the AVF. The endovascular embolization has been reported as successful, as it is less aggressive and carried out in the same occasion of the angiography.<sup>6,7,21</sup> And yet, divergent opinions still remain about its effectiveness. Morandi *et al.*<sup>19</sup> question it for considering that the technique is not able to embolize the collateral arteries. Muthukumar *et al.*<sup>21</sup> believe that the embolization has its value for cases where only one artery or small vessels irrigate the AVF. In cases of plexiform fistulas (multiple fistulas characterizing a plexiform irrigation), embolization is recommended followed by surgery. The complications of the treatment with endovascular embolization are superficial necrosis of the scalp, recurrence (both also seen in the surgical procedure), formation of multiple aneurisms and migration of embolic fistulas of high flow.<sup>2,21,23</sup>

The treatment of choice is the total surgical excision of the lesion. In general, the surgical access is easy but in case the previous embolization has been performed, the surgeon must avoid possible adhesions. In proximal AVFs there are the risks of iatrogenic lesions of the zygomatic and frontal branches of the facial nerve and the parotid gland.<sup>24</sup> In case the lesion cannot be excised completely for presenting an excessive number of vessels, and the local skin is too thin, Muthukumar *et al.*<sup>21</sup> suggest in bloc resection with subsequent plastic reconstruction. The morbidity and the chance of failure are little to none.<sup>24</sup>

In the case presented it was chosen to clip the pseudoaneurysm aiming the prevention of bleedings after the full resection of the lesion. The surgical procedure took place without any complication.

## Fundings

None.

## Conflict of interest

There is no conflict of interest to declare.

## REFERENCES

- Hendrix LE, Meyer GA, Erickson SJ. Cirroid aneurysm treatment by percutaneous injection of sodium tetradecyl sulfate. *Surg Neurol.* 1996;46(6):557-60; discussion 60-1.
- Miekisiak G, Mis M, Sandler A, et al. Iatrogenic arteriovenous fistula of the superficial temporal artery. *Oral Maxillofac Surg.* 2008;12(4):219-21.
- Moran AM, Aleman TS, Gausas RE, et al. Traumatic arteriovenous fistula of the superficial temporal artery: a histopathologic report. *Ophthal Plast Reconstr Surg.* 2013;29(5):e126-8.
- Rosenblum MK. Central nervous system. In: Rosai J, editor. *Rosai and Ackerman's surgical pathology.* 2. 10th ed. Edinburgh: Mosby Elsevier; 2011. p. 2308-17.
- Takeuchi S, Takasato Y. Iatrogenic arteriovenous fistula of the superficial temporal artery after manual reduction of temporomandibular joint dislocation. *J Craniofac Surg.* 2011;22(5):1959-61.
- Amlashi SF, Riffaud L, Morandi X. Arteriovenous fistula of the superficial temporal artery: an exceptional complication of the pterional approach. *J Neurol Neurosurg Psychiatry.* 2004;75(7):1077-8.
- Leal FS, Miranda CC, Guimaraes AC. Traumatic pseudoaneurysm of the superficial temporal artery: case report. *Arq Neuropsiquiatr.* 2005;63(3B):859-61.
- Zanini MA, Ferreira ITA, Freitas CCM, et al. Pseudoaneurisma traumático gigante da artéria temporal superficial: relato de caso com 11 anos de evolução. *Arq Bras Neurocir.* 2007;26(2):72-6.
- Bole PV, Munda R, Purdy RT, et al. Traumatic pseudoaneurysms: a review of 32 cases. *J Trauma.* 1976;16(1):63-70.
- Angevine PD, Connolly ES. Pseudoaneurysms of the superficial temporal artery secondary to placement of external ventricular drainage catheters. *Surg Neurol.* 2002;58(3-4):258-60.
- Fernandez-Portales I, Cabezudo JM, Lorenzana L, et al. Traumatic aneurysm of the superficial temporal artery as a complication of pin-type head-holder device. Case report. *Surg Neurol.* 1999;52(4):400-3.
- Rich NM, Hobson RW, Collins GJ. Traumatic arteriovenous fistulas and false aneurysms: a review of 558 lesions. *Surgery.* 1975;78(6):817-28.
- Ishikawa E, Sugimoto K, Yanaka K, et al. Giant aneurysm of the superficial temporal artery. Case report and review of the literature. *Surg Neurol.* 2000;53(6):543-5.
- Calwell EI, McKinstry CS, Kendrick RW. Arteriovenous fistula after temporomandibular arthroscopy. *Br J Oral Maxillofac Surg.* 1999;37(2):127-8.
- Hong JT, Lee SW, Ihn YK, et al. Traumatic pseudoaneurysm of the superficial temporal artery treated by endovascular coil embolization. *Surg Neurol.* 2006;66(1):86-8.
- Marks MW, Argenta LC, Dingman RO. Traumatic arteriovenous malformation of the external carotid arterial system. *Head Neck Surg.* 1984;6(6):1054-8.
- Manz HJ, Gomes MN. Sports injury as cause of traumatic pseudoaneurysm of superficial temporal artery. *Arch Pathol Lab Med.* 1984;108(10):775-6.
- Moreira RCR, Miyamoto M, Jarabiza R. Late arterial aneurysms associated with history of traumatic arteriovenous fistulas. *J Vasc Br.* 2004;3(3):265-8.
- Morandi X, Godey B, Riffaud L, et al. Nontraumatic arteriovenous fistula of the superficial temporal artery. *Otolaryngol Head Neck Surg.* 2001;124(5):588-9.
- Lai JP, Hsieh CH, Chen YR, et al. Unusual late vascular complications of sagittal split osteotomy of the mandibular ramus. *J Craniofac Surg.* 2005;16(4):664-8.

21. Muthukumar N, Rajagopal V, Manoharan AV, et al. Surgical management of cirroid aneurysms. *Acta Neurochir (Wien)*. 2002;144(4):349-56.
22. Whiteside OJ, Monksfield P, Steventon NB, et al. Endovascular embolization of a traumatic arteriovenous fistula of the superficial temporal artery. *J Laryngol Otol*. 2005;119(4):322-4.
23. Kim DM, Benndorf G, Von Moers A, et al. Spontaneous scalp arteriovenous fistula in a child with hartnup disease. *J Endovasc Ther*. 2004;11(3):348-50.
24. Guedes-Correa JF, Souza ABM, Vaitsman RP, et al. Pseudoaneurisma traumático de ramo frontal da artéria temporal superficial: relato de caso. *Arq Bras Neurocir*. 2006;25(1):40-3.