

# Primary cerebrospinal fluid leak complicated with meningitis and parainfectious vasculitis: case report and literature review

## *Fístula liquórica primária complicada com meningite e vasculite parainfecciosa: relato de caso e revisão de literatura*

Raíssa Habka Cariello<sup>1</sup>, Marcelo Ricardo Canuto Natal<sup>2,3</sup>, Eduardo Waihrich<sup>4</sup>, Talyta Grippe<sup>5,6</sup>

### ABSTRACT

This paper aims to describe a case of an immunocompetent 60-year-old patient presenting a subarachnoid hemorrhage in the absence of aneurysmal disease. Initial evaluation pointed to vasculitis of the central nervous system secondary to meningeal infection. After initial treatment, a cerebrospinal fluid leak was identified, with no antecedent of trauma, elucidating the origin of infection. Primary cerebrospinal fluid rhinorrhea has nonspecific symptomatology, defying diagnosis, and potentially serious complications. It represents an unusual predisposing factor for meningeal infection and secondary vasculitis. This case report exemplifies a feared complication of spontaneous cerebrospinal fluid leakage.

**Keywords:** Cerebrospinal Fluid Rhinorrhea, Meningitis, Vasculitis.

### RESUMO

O estudo objetiva relatar um caso clínico de uma paciente imunocompetente de 60 anos apresentando hemorragia subaracnoide na ausência de doença aneurismática. Avaliação inicial apontou para vasculite de sistema nervoso central secundária à infecção meníngea. Após tratamento inicial, uma fístula liquórica foi identificada, sem antecedente de trauma, elucidando a origem da infecção. Rinorreia liquórica primária possui sintomatologia inespecífica, diagnóstico desafiador e complicações potencialmente graves. Representa um raro fator predisponente para infecção meníngea e vasculite. Este relato de caso exemplifica uma complicação temida da rinorreia liquórica espontânea.

**Palavras-chave:** Rinorreia de Líquido Cefalorraquidiano, Rinorreia Liquórica, Meningite, Vasculite.

<sup>1</sup> Estudante de Medicina, Centro Universitário de Brasília (UniCEUB), Distrito Federal, Brasil.

<sup>2</sup> Médico radiologista do Hospital de Base do Distrito Federal (HBDF), Brasília, Brasil.

<sup>3</sup> Médico radiologista do Sabin Medicina Diagnóstica, Brasília, Brasil.

<sup>4</sup> Médico neurocirurgião do Hospital de Base do Distrito Federal (HBDF), Brasília, Brasil.

<sup>5</sup> Docente do curso de Medicina do Centro Universitário de Brasília (UniCEUB), Distrito Federal, Brasil.

<sup>6</sup> Médica neurologista do Hospital de Base do Distrito Federal (HBDF), Brasília, Brasil.

### Correspondence author:

Talyta Grippe, Centro Universitário de Brasília (UniCEUB), Distrito Federal, Brasil.

E-mail: talytagrippe@gmail.com

## INTRODUCTION

Cerebrospinal fluid (CSF) rhinorrhea most often derives from trauma but may arise spontaneously in a minority of cases<sup>1,2</sup>. Spontaneous CSF leakage is more prevalent in middle-aged women<sup>3</sup>. It may lead to potentially fatal cerebrovascular complications and thus urges early diagnosis and intervention<sup>2,3</sup>. This case report refers to an immunocompetent 60-year-old patient with spontaneous CSF leak complicating with meningitis and focal parainfectious vasculitis.

## CASE REPORT

A 60-year-old overweight woman was admitted with fever, emesis, myalgia, arthralgia, and prostration. The patient's past medical history was notable for tabagism, diabetes, hypertension, and migraine. She was in a regular state, alert and febrile. The patient complained of an acute headache and presented a tonic-clonic seizure and multiple focal seizures, followed by dysarthria and right hemiparesis after the post-ictal phase. Pupils were isocoric and fotoreactive. Head computed tomography (CT) revealed a subarachnoid hemorrhage in the left Sylvian fissure without neurosurgical indication. CSF analysis was compatible with an inflammatory pattern (**Table 1**).

Table 1: Cerebrospinal fluid analysis

Color	Colorless
Turbidity	Clear
Xanthochromia	None
Red-cell count (per mm <sup>3</sup> )	0
Total nucleated-cell count (per mm <sup>3</sup> )	18
Differential count (%)	
Neutrophils	0
Lymphocytes	89
Monocytes	11
Protein (g/dL)	39
Glucose (g/dL)	118
Gram staining, Ziehl-Neelsen staining, fungus	Negative
Treponema pallidum	Negative

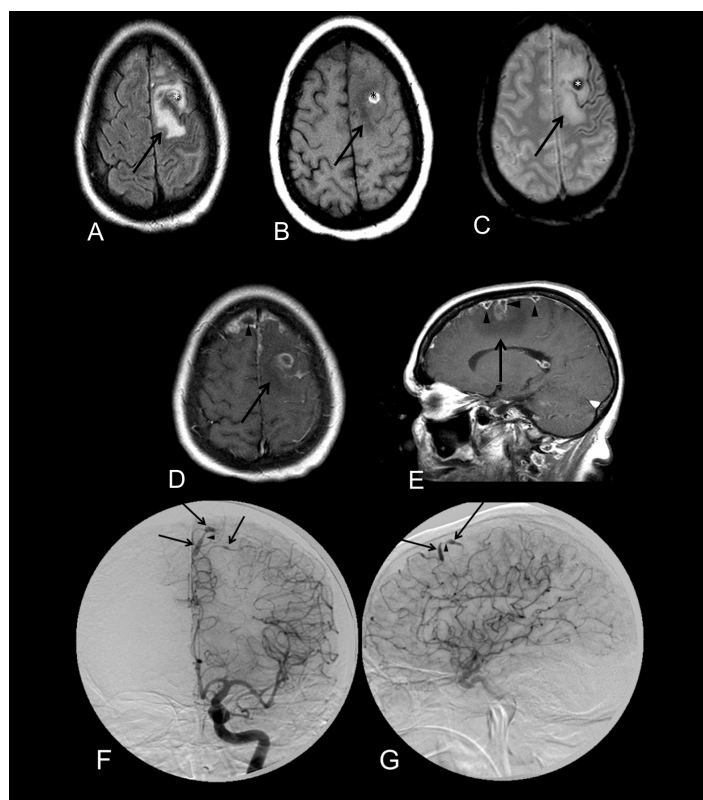


Figure 1: A-E: Brain MRI: axial images in sequences of FLAIR (A), T1-weighted (B), T2-weighted (C), T1-weighted post contrast (D), and sagittal T1-weighted post contrast (E). Lesion with vasogenic edema in frontal superior gyrus and pre-central gyrus of the left frontal lobe (arrows) with a hemorrhagic spot (\*).

Post contrast imaging shows leptomeningeal enhancement with foci of empyema (arrow heads).

F and G: Digital angiography of the left internal carotid artery in frontal (F) and lateral (G) incidences showing focal dilations (arrows) with interposed stenosis (arrow heads) in middle internal frontal artery (branch of the anterior cerebral artery).

Magnetic resonance imaging (MRI) of the brain and angiography were compatible with empyema and vasculitis (Figure 1). Anti-ribonucleoprotein, anti-cardiolipin IgM and IgG, anti-Ro, anti-La, anti-Sm, lupic anticoagulant were negative. C3, C4 and beta-2-microglobulin levels were normal. Serum testing for HIV, hepatitis B and C, and Treponema Pallidum were negative. Electroencephalogram showed basal disorganization and polymorphic delta activity.

Posteriorly, it was identified a right nasal drainage, which the patient presented since 2013 but did not complain

until this point. She described this symptom as refractory to conservative approaches for rhinosinusitis. Associated symptoms included remittent headaches, hypoacusis, and gait unsteadiness. She denied previous head trauma. CT of paranasal sinuses revealed indirect signs of CSF fistula (Figure 2). Nasofibroscope without fluorescein was normal. Analysis of rhinorrhea fluid showed presence of glucose, compatible with CSF.

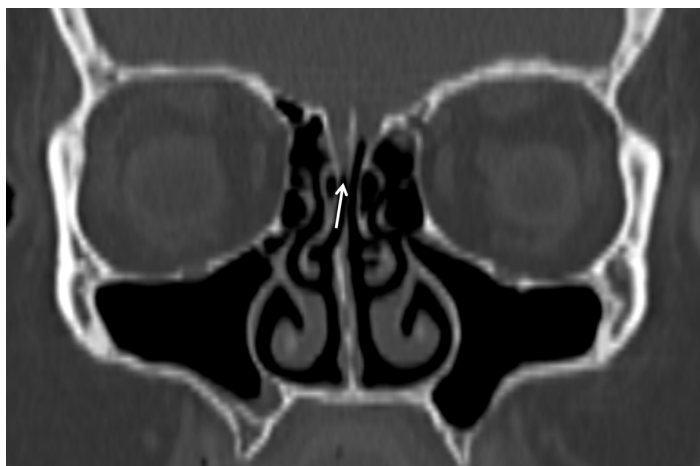

Figure 2: CT of paranasal sinuses in coronal incidence showing an inferior positioning of the cribriform plate of the ethmoid bone (arrow) in the right side in comparison with the left side. Surgical procedure confirmed the presence of a meningoencephalocele.

Surgical approach confirmed presence of a meningoencephalocele (diameter of 0,5cm) with a central fistula in the ethmoid bone. Neurological examination during follow-up revealed minimal sequelae and resolution of rhinorrhea, headache, and seizures. Her final diagnosis was vasculitis secondary to local infection due to spontaneous CSF fistula.

## DISCUSSION

CSF rhinorrhea is an osteomeningeal breach that extends from the anterior skull base to the paranasal sinuses<sup>2,3,4,5</sup> predisposing to serious complications, such as abscess, encephalocele, and meningitis. Early diagnosis and fastidious intervention are thus important<sup>2,3,4,6</sup>.

CSF leaks often develop from trauma, whereas primary CSF rhinorrhea has no identifiable cause as in this case report. Risk factors are: obesity, female gender, and middle age<sup>3,5</sup>. The most common sites of spontaneous CSF leaks are sphenoid sinus and cribriform plate<sup>3,5</sup>. In contrast, in this case report the osteomeningeal defect lies in the ethmoid sinus.

Clinical presentation may be limited to the nasal drainage alone, frequently leading to the misdiagnosis of

rhinitis or upper respiratory tract infection. Headaches and signs of gravity (neck stiffness, fever, seizures) may also manifest.

CT scan is most widely used to detect the anatomic defect in the skull base<sup>5</sup> and can be combined with CT cisternography to better characterize the leakage<sup>1</sup>. MRI may provide further details that can be helpful for preoperative planning<sup>1,5</sup>. Specific serum tests can be made to exclude systemic disorders that predispose to connective tissue disorders, which represent a risk factor for the development of spontaneous CSF leaks<sup>7</sup>. Analysis of rhinorrhea with  $\beta$ -2 transferrin assay<sup>5</sup> and quantification of glucose<sup>8</sup> should be done to confirm its CSF constitution. Lumbar puncture should be performed when suspecting of meningitis.

Meningovascular complications can occur in the context of primary CSF leaks. Vasculitis is a rare, non-atherosclerotic cause of cerebrovascular disease<sup>9,10</sup>. Vasculitis secondary to infection is much more prevalent than primary vasculitis. Infectious pathogens may directly injure the vessel walls or might indirectly contribute to inflammation of vascular structures through immune-mediated mechanisms<sup>4,11,12</sup>. Exceptionally, vasculitis can cause subarachnoid hemorrhage as exemplified in this case report<sup>4,10,11</sup>.

Vascular complications of bacterial meningitis may emerge during the onset of disease or following antimicrobial treatment through: (a) vascular infiltration of inflammatory exudate in the subarachnoid space, (b) edema and intimal thickening induced by inflammation, and (c) vasospasm in the absence of other abnormalities<sup>4,11</sup>. Vasculopathy secondary to human immunodeficiency virus infection is linked to the formation of immune deposits and direct viral invasion of the endothelium<sup>4,10,11</sup>. *Treponema pallidum* infection has been associated with giant cell arteritis<sup>4,11,12</sup>. Inflammatory exudates, vasospasm, and subsequent infarction are plausible pathologic phenomena in tuberculous vasculopathy<sup>4,11</sup>. Numerous other pathogens have the potential to cause meningovascular complications, such as varicella-zoster virus and aspergillosis<sup>4,11</sup>.

Although histopathological analysis is the gold standard for diagnosis of central nervous system (CNS) vasculitis<sup>4,9,11</sup>, it involves an invasive procedure with sensitivity of approximately 70%<sup>4,11,13</sup>. Brain biopsy is therefore not routinely performed. Neuroimaging can reveal leptomeningeal enhancement and vessel "beading" (alternating dilatation and stenosis of vessel walls)<sup>13,14</sup>. In CNS vasculitis, liquor analysis is frequently abnormal (80-90% of cases of

primary CNS vasculitis pathologically confirmed) usually in the form of aseptic meningitis<sup>11,13</sup>.

The therapeutical approach of a secondary vasculitis relies on the resolution of the underlying etiology. Glucocorticoids can be administered temporarily to control inflammation<sup>11</sup>. Treatment of CNS vasculitis lacks strong evidence-based guidelines, despite the improvement of the medical management of this condition in the last decades.

## CONCLUSION

Primary cerebrospinal fluid rhinorrhea is a challenging condition for clinical practitioners due to its nonspecific symptomatology, defying diagnosis, and serious complications. Clinical presentation may be limited to the nasal drainage alone, frequently leading to the misdiagnosis of rhinitis or upper respiratory tract infection. Invasion of the CNS by infectious agents is a feared complication, which can cause further cerebrovascular events. It is important to describe this case in order to call attention for the primary cerebrospinal fluid leak as an unusual predisposing factor for secondary CNS vasculitis.

## CONFLICT OF INTEREST

The author declares that there is no conflict of interest.

## FUNDING STATEMENT

There is no financial support.

## REFERENCES

1. Chen GY, Xu ML, Zhang JN et al. Spontaneous cerebrospinal fluid rhinorrhea. *Medicine*. 2018;97(5):e9758 .
2. Deconde AS, Suh JD, Ramakrishnan VR. Treatment of cerebrospinal fluid rhinorrhea. *Curr Opin Otolaryngol Head Neck Surg*. 2015;23(1):59-64.
3. Giannetti AV, de Moraes Silva Santiago AP, Becker HM, Guimarães RE. Comparative study between primary spontaneous cerebrospinal fluid fistula and late traumatic fistula. *Otolaryngol Head Neck Surg*. 2011;144(3):463-8.
4. Chow FC, Marra CM, Cho TA. Cerebrovascular disease in central nervous system infections. *Semin Neurol*. 2011;31(3):286-306.
5. Lobo BC, Baumanis MM, Nelson RF. Surgical repair of spontaneous cerebrospinal fluid (CSF) leaks: A systematic review. *Laryngoscope Investig Otolaryngol*. 2017;2(5):215-24.
6. Bjerre P, Lindholm J, Gyldensted C. Pathogenesis of non-traumatic cerebrospinal fluid rhinorrhea. *Acta Neurol Scand*. 1982;66(2):180-90.
7. Mokri B. Spontaneous Intracranial Hypotension Spontaneous CSF Leaks. *Headache Curr*. 2005;2(1):11-22.
8. Manson PN. Assessment and management of facial injuries. *Plast Surg Secrets*. 2010;275-81.
9. Barros MT, Barros RT. Vasculites : classificação, patogênese e tratamento. *Rev. bras. alergía imunopatol*. 1998;21(4):128-138.
10. Demir S, Sönmez HE, Özen S. Vasculitis: Decade in Review. *Curr Rheumatol Rev*. 2019;15(1):14-22.
11. John S, Hajj-Ali RA. CNS vasculitis. *Semin Neurol*. 2014;34(4):405-12.
12. Belizna CC, Hamidou MA, Levesque H, Guillemin L, Shoenfeld Y. Infection and vasculitis. *Rheumatology*. 2009;48(5):475-82.
13. Byram K, Hajj-Ali RA, Calabrese L. CNS Vasculitis: an Approach to Differential Diagnosis and Management. *Curr Rheumatol Rep*. 2018;20(7):1-7.
14. Abdel Razek AAK, Alvarez H, Bagg S, Refaat S, Castillo M. Imaging spectrum of CNS vasculitis. *Radiographics*. 2014;34(4):873-94.