

Trochlear nerve: Celebrating 500 years of description

Nervo troclear: Comemorando 500 anos de descrição

Janaina Santos Mendes, MD in progress¹ Orcid: <https://orcid.org/0000-0002-2694-0880>

Karine Santos de Freitas, MD in progress¹ Orcid: <https://orcid.org/0000-0002-0377-2175>

Marcus André Acioly, MD, PhD^{1,2} Orcid: <https://orcid.org/0000-0003-3998-2171>

Marleide da Mota Gomes, MD, PhD³ Orcid: <https://orcid.org/0000-0001-8889-2573>

ABSTRACT

The history of the description and classification of the cranial nerves has paralleled the development of anatomy and its role in providing rationality to medicine. About five hundred years ago, the “Anatomical Notes by the Great Alexander Achillinus of Bologna” (1520) provided the first description of the trochlear nerve. In this article, we review the most important macroscopic achievements through different epochs and pioneers such as Herophilus of Chalcedon, Galen of Pergamon, Andreas Vesalius, Bartolomeo Eustachi, Realdo Colombo, Gabriele Falloppio, Antonio Molinetti, Caspar Bartholin, Thomas Willis and Samuel Thomas von Soemmerring. Each of them contributed to a better understanding of the cranial nerves as we know today. Galen's classification was enduring through his seven pairs of cranial nerves. Realdo Colombo coined the name pathetic nerve or nervus oculorum pateticos to the trochlear nerve in 1559, and Molinetti, nervus trochlearis, in 1669. The term trochlear nerve is derived from the Latin word pulley, trochlea, as it innervates the superior oblique muscle that ends in a tendon that bends through a pulley of connective tissue. Besides description and naming, the inclusion into current cranial nerve classification system and how such knowledge applies to current microsurgical understanding is also discussed.

Keywords: Cranial nerves, trochlear nerve, history of Medicine

RESUMO

A história da descrição e da classificação dos nervos cranianos acompanhou o desenvolvimento da anatomia e o seu papel na racionalidade da medicina. Cerca de quinhentos anos atrás, as “Notas Anatômicas do Grande Alexandre Achillini de Bolonha” (1520) forneceram a primeira descrição do nervo troclear. Neste artigo, revisamos as realizações macroscópicas mais importantes em diferentes épocas e damos crédito aos pioneiros como Herófilo de Calcedônia, Galeno de Pérgamo, Andreas Vesalius, Bartolomeo Eustachi, Realdo Colombo, Gabriele Falloppio, Antonio Molinetti, Caspar Bartholin, Thomas Willis e Samuel Thomas von Soemmerring. Cada um deles contribuiu para uma melhor compreensão dos nervos cranianos, como os conhecemos hoje. A classificação de Galeno perdurava através de seus sete pares de nervos cranianos. Realdo Colombo cunhou o nome nervo patético ou nervus oculorum pateticos para o nervo troclear em 1559, e Molinetti, nervus trochlearis, em 1669. O termo nervo troclear é derivado da palavra latina polia, tróclea, pois inerva o músculo oblíquo superior que termina em um tendão que se dobra através de uma polia de tecido conjuntivo. Além da descrição e da nomenclatura, também é discutida a inclusão do nervo troclear no atual sistema de classificação de nervos cranianos e como esse conhecimento se aplica à compreensão microcirúrgica atual.

Palavras-chave: Nervos cranianos, nervo troclear, história da Medicina

¹Division of Neurosurgery, Federal University of Rio de Janeiro (UFRJ) – Rio de Janeiro, Brazil;

²Division of Neurosurgery, Fluminense Federal University, Niterói – Rio de Janeiro, Brazil;

³ Laboratory of History of Psychiatry, Neurology, and Mental Health, Institute of Psychiatry. Institute of Neurology. Federal University of Rio de Janeiro, Rio de Janeiro, Brazil..

Corresponding author: Marcus André Acioly, MD, PhD Division of Neurosurgery, Department of Surgical Specialties
Federal University of Rio de Janeiro, Rio de Janeiro, Brazil
e-mail: marcusacioly@yahoo.com.br

INTRODUCTION

The history of the description and classification of the cranial nerves has paralleled the development of anatomy and its role in providing rationality to medicine¹. Distinguished anatomists have contributed to the field³ considering the well-recognized disagreement on cranial nerve accounts and classification systems¹. Porrás-Gallo et al.¹ divided the history of the cranial nerves into three main periods, namely, the first (early or macroscopic), second (microscopic), and third (ontogenetic and genoarchitecture) periods.

In the macroscopic period, major interests were focused on the definition of cranial nerve number and course, and according to Ballester², it was credited to Herophilus of Chalcedon (335-280 b.C.), who was one of the main members of the Alexandrian School, the discovery of seven pairs of cranial nerves^{1,3}. Besides, Galen of Pergamon (129-217), who was inspired by previous anatomical legacies, recognized the olfactory nerve as a 'cerebral nerve'. He also chose to keep the numeric system of classification of seven pairs of cranial nerves, which was described by his mentor Marinus (ca. 130), and he did not assign any specific names to the nerves^{3,4}, however, Galen just referred to the oculomotor nerve as terminating in the 'muscles, which move the eye'³⁻⁵.

Even though Galen organized and structured anatomical knowledge for the first time², it was not reliable to trace a correlation to human anatomy, since most of his anatomical research was based on animal dissection and vivisection^{1,4}. Remarkably, Galen only recognized seven pairs of cranial nerves: I, optic; II, oculomotor; III and IV, trigeminal; V, facial and auditory; VI, glossopharyngeal, vagus and accessory; VII, hypoglossal¹. Indeed, the great renowned Roman physician realized that apes were more like humans than bovines and alerted earlier physicians of such anatomical features⁴. Such misunderstanding of the human anatomy has lasted about 1,200 years before his description of the cranial nerves was questioned during the Italian Renaissance when human dissection allowed for corrections in his observations¹.

The trochlear nerve, which is also named pathetic or the fourth cranial nerve, was the last of the 12 cranial nerves to be recognized. It has many particularities that make it obscure to many anatomists: (1) it has a dorsal exit from the brainstem, (2) its nucleus lies on the opposite side and it decussates in the superior medullary velum, (3) it is an exclusive motor nerve that innervates the superior oblique muscle, (4) it is the thinnest cranial nerve (0.75–1.0 mm) with the longest intracranial course (60 mm), and (5) proper specimen fixation techniques were only available after the 18th century^{3,6,7}.

Consequently, because of its length, the precise knowledge of its surgical anatomy and its neurovascular relationships is fundamental for safely approaching and

removing complex lesions of the orbit and the middle and posterior fossae. In this article, we review the history behind the description, naming, and inclusion of the trochlear nerve into the current cranial nerve classification system and how such knowledge applies to current microsurgical understanding.

THE DESCRIPTION OF THE TROCHLEAR NERVE INSIDE CRANIAL NERVES CLASSIFICATIONS

Alessandro Achillini (1463–1512) was an Italian philosopher and physician who was known as a distinguished anatomist, and he was probably the first to describe the trochlear nerve, but he neither named nor illustrated it⁸. He was well versed in theology, and member of an old family of Bologna. Humble, handsome, and smiling, he was admired as a teacher, Magnus Achillinus. Achillini taught Medicine and/or Philosophy at the University of Bologna for 28 years (1484-1512), except for a two-year interim (1506-1508), when he began teaching at the University of Padua.

In his book 'Anatomical Notes by the Great Alexander Achillinus of Bologna' (1520) (Achillini and Achillini 1520, XIII), which was published posthumously by his brother Giovanni Filoteo (1466-1538)¹, the trochlear nerve is identified, and its functional role was also determined. This book was issued in a small format of eighteen folios and compared his findings to previous pioneer descriptions, like Galen and Avicenna, taking note of their similarities and divergences⁸. He wrote another book, *De humani corporis anatomia*, and described many other anatomical structures⁹. Soemmerring considered the description of the trochlear nerve to be the first significant acquisition after Galen¹⁰. According to Lind¹¹, Achillini is the only who has made new discoveries in general anatomical dissections in the Pre-Vesalian period.

TROCHLEAR NERVE NAMING AND INCLUSION INTO CRANIAL NERVE CLASSIFICATION SYSTEMS

In 1543, Andreas Vesalius (1514-1564), the "father of modern anatomy", followed Galen's system of seven pairs of cranial nerves. The trochlear nerve is clearly distinguished in its anatomical illustrations, but its origin from the brainstem and its inclusion in the cranial nerve classification system was not considered^{12,13}. Following Vesalius, Matteo Realdo Colombo (c. 1515 – 1559), who was an Italian professor of anatomy and a surgeon at the University of Padua in 1559, numbered the trochlear nerve the ninth cranial nerve and gave further elucidation to its function by innervating the fifth ocular muscle (Realdo Colombo 1559, 124)¹⁴. He also recognized trochlear nerve origin from the brainstem (Realdo Colombo 1559, 198)^{14,2}

¹"Est aliud par neruorum subtile exiens a posteriori cerebri trāsiens ad anteriora super loco aurium: de quo nihil inueni a doctoribus puto que det motum superciliis: statim apparet cum eleuatur cerebrum." (There is another pair of delicate nerves coming out from the back of the brain and passing to the front over the ears, which is believed by the doctors to move the eyebrows and immediately becomes apparent as soon as the brain is lifted). (Achillini and Achillini 1520).

Gabriele Falloppio (1523-1562) was an Italian Catholic priest and anatomist who occupied the chair of anatomy and surgery at the University of Padua, and in 1561 he expanded the Vesalius' cranial nerve classifications, and he kept the oculomotor nerve as the second pair but assigned the abducens nerve as the fourth and the trochlear nerve as a new pair, the eighth cranial nerve^{18,19}. Falloppio made a clear distinction and description of the trochlear nerve, from its origin in the brainstem and its course to reach the superior oblique muscle, which was "reflected on a cartilaginous pulley, and it turns the eye inwards"²⁰. Such cartilaginous pulley was also known as "trochileia", a Latin word for pulley or reel.

Bartolomeo Eustachi (ca. 1500/1510-1574), professor of Medicine at the Collegia della Sapienza in Rome, prepared beautiful engravings for the complete edition of treatises dedicated to specific organs of the body in 1564, but only 8 were published at the time^{21,22}. Later, Giovanni Maria Lancisi printed them in *Tabulae anatomicae* in 1714³, and in its Tabula XVIII, in which there was a distinct representation of the oculomotor, trochlear, and abducens nerves. Regarding the trochlear nerve, Eustachi said: "The fourth pair, called the pair of the pathetic nerves by the moderns, because it is the finest of all those which arise inside the skull, originates in the lower part of the medulla oblongata, and next to the nerves oculo-motors...". According to Hierons and Meyer¹⁹, the origin of the term pathetic is certainly related to Realdo Colombo's description of the fifth ocular muscle function of a merciful look at Heaven. However, he mistakenly claimed in *De re anatomica libri XV* that the nerve would favor the upward gaze of the eye³.

In 1664, Thomas Willis (1621-1675)²³, remembered as "the founder of clinical neuroscience" and a pioneer of modern translational research in anatomy, enumerated and illustrated nine cranial nerve pairs, including the olfactory nerves as the first pair. Moreover, Willis counted the trochlear, trigeminal, and abducens nerves individually and numbered them consecutively in their present order as IV to VI. Besides, Caspar Bartholin the elder (1585 – 1629) who was a Danish physician, anatomist, and theologian was potentially the only one before Willis to number the olfactory and trochlear nerves correctly in 1632²⁴.

The term *nervus trochlearis*, first appeared in the literature in 1669, was assigned by Antonio Molinetti²⁵ Paduan anatomist (c1610/5-1675); (Molinetti 1669, 65)⁴. The main books of anatomy with innovative remarks by,

Vesalius (1543), Eustachi (1564/1714), Willis (1664) and Soemmerring (1778) about the trochlear nerve are presented in Figure 1.

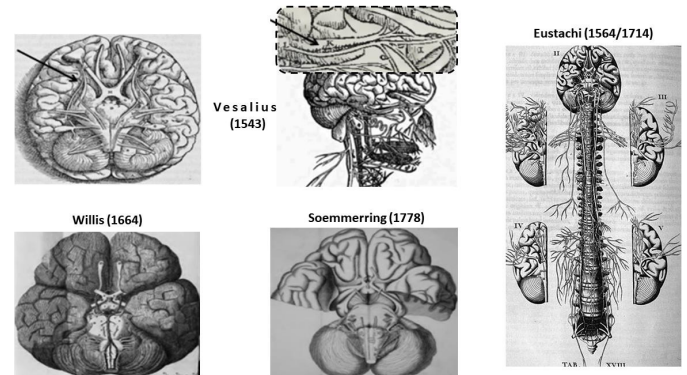


Figure 1. Relevant historical depictions of the cranial nerves, with emphasis on the trochlear nerve according to Andreas Vesalius (see arrows), Bartolomeo Eustachi, Thomas Willis and Samuel Thomas von Soemmerring. Willis and Soemmerring depicted the emergence of the trochlear nerves at the brainstem. Public domain

Samuel Thomas Soemmerring (1755–1830), a Prussian polymathic doctor with remarkable achievements in anatomy, and draftsmanship, also considered the description of the trochlear nerve by Achillini to be the first significant acquisition after Galen¹⁰ (Figure 2).

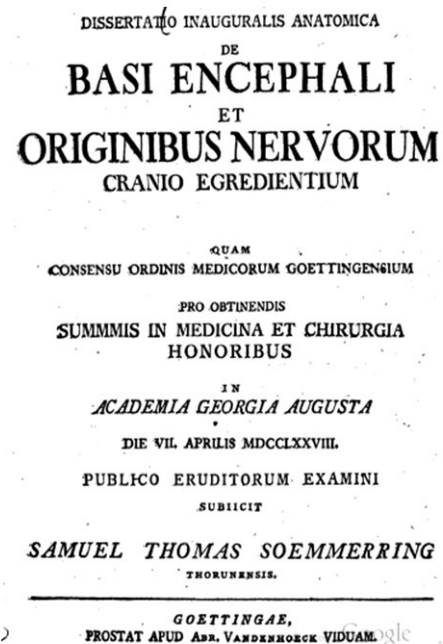


Figure 2. Soemmerring's 12 pair classification of the cranial nerves, dissertation frontispiece.

²⁴Nonum par neruorum cuius neq; Vessalius ipse verbum fecit, quodq; ego primus inueni; est neruorum exilium par ortum ducens à binis illis cerebri processibus, qui nates appellantur penes testes; tenues fatis sunt, & exiles vt dixi: faciem versus accedunt, transeuntq; apud tertium, & secundum par, atque in tertium palpebrae musculum inseruntur, ramulus tamen huius noni paris ad quintum musculum oculi deferitur.*

(The ninth pair of nerves, which Vesalius himself named, and I discovered first; are the nerves that leave near the elevation of the two brain processes, which are called nates* [buttocks] [superior quadrigeminal bodies] near the testes [testicles] [inferior quadrigeminal bodies]; they are rendered thin, and leave as mentioned, ascends away towards the face, with the third and the second pairs, and are inserted in the third muscle of the eyelids, and a small branch of the ninth pair provides the fifth eye muscle**.) (Realdo Colombo 1559).

* Galen described the lamina quadrigemina as having two pairs of rounded structures: the first, "the gloutia" [nates], and the second, "the testes", or "the twins", that are associated with the pineal gland (Rocca, p 149)¹⁵.

**Regarding the ocular muscles, du Laurens (1593)¹⁶ recognizes that they are six, four are the recti, and two are the obliques. There are two obliques, and they encircle the eye obliquely, one above [superior oblique muscle] and one below [inferior oblique muscle]. The first [superior oblique muscle] ascent of the inner orbit, like the upper four, is centered at a higher angle, and there on a thin cord unknown to the ancients, which is elegantly described and defined first by Fallopius, which encircles like a pulley (trochlea), it is inserted obliquely on the conjunctival side. The posterior part, also slenderer, rises from the internal angle and inserts into the external part of the tunic. According to du Laurens, he gave each of these muscles a name with a childlike trait, the first one stands up and says he is proud [superior rectus muscle]; the second is depressed and humble [inferior rectus muscle], the third adductor and drunk [internal rectus muscle], the fourth abducting and indignant [external rectus muscle]; two obliques [superior and inferior oblique muscles] turning, lovingly, as if leading to love. In his description, Realdo Colombo (1559) has linked the "fifth eye muscle" [superior oblique muscle] to the ninth pair of cranial nerves, which was recognized as the "pathetic nerve" or nervus oculorum pateticos afterwards because he mistakenly attributed the function of upward gaze to that muscle. Vesalius' contribution was small, but the great contribution was stressed by Johann Gottfried Zinn (1727-1759), as seen in his treatise Descriptio Anatomica Oculi Humani, 1755¹⁷.

Many cranial nerve classifications existed the long-lasting one was that of Galen, as unfolded in Figure 3. The current classification system, which is composed of 12 pairs of cranial nerves, is based on the scheme presented by Soemmerring in his doctoral thesis in 1778¹⁰. Soemmerring's classification gained instant recognition²⁶, which was rapidly adopted throughout continental Europe³. At that time, he believed that cranial nerves emerged from the ventricular walls²⁶.

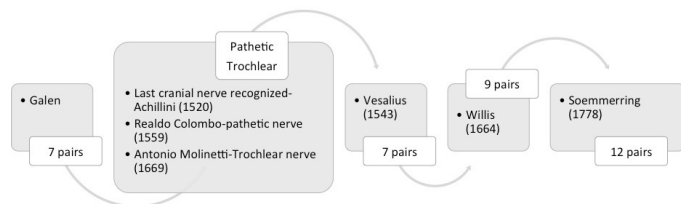


Figure 3. Milestones of trochlear nerve definitions and major cranial nerve classifications.

Even though Soemmerring made no relevant anatomical discoveries in comparison to his predecessors, he was the first to use the term “nervus abducens”^{3,26}. Before him, the facial and vestibulocochlear nerves were considered a single nerve. Besides, he named the facial nerve branch – the nervus *intermedius* of Wrisberg, in deference to his teacher²⁶. Finally, Soemmerring divided the eighth cranial nerve into glossopharyngeal, vagus, and spinal accessory nerves^{10,26}.

Figure 4 presents ten outstanding anatomists, including Achillini, who contributed to the classification of cranial nerves.

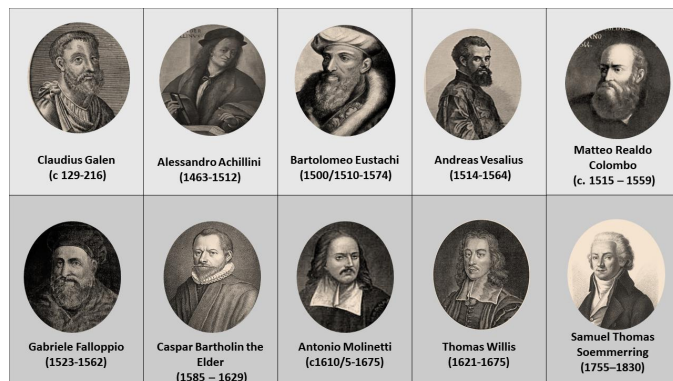


Figure 4. Ten outstanding anatomists who influenced the understanding of trochlear nerve macroscopic anatomy. Pictures of public domain.

³“Hunc neruum si attrahas, oculus sursum vertitur, & circumagitur; quanvis musculus subsit forte hic fuit usus huius musculi admirabilis, ut eius auxilio coelum, diuinaeq; maiestatis fabricam intueremur, ad quod nati sumus;” (This should attract the nerve, the eye is then turned up & around; when the muscle subsides strongly. This was the function of this admirable muscle with its assistance, the divine and majestic design of the heaven are gazed, in which we are born) (Realdo Colombo 1559).

⁴“Sextum locum, nouem combinationes enumerantibus, trochlearis neruum sibi vindicat, quom Fallopiantum etiam vocant, ab eo Auctore. Prodit nerulus, omnium minimus, ex Ponte, paulò suprâ diuicationes Quarti, & Quinti, è regione sellicet Natis, & Testis sui lateris; atq; marginibus prioribus Cerebelli accumbens, tectus immediate à Processu secundum durae Meningis, obliquo ducto, in oculum properat, admissio in consortium itineris ramulo priori nerui Quarti, in oculi motorem obliquum superiorem distribuitur, qui Trochlearis olim appellatus, neruo nomen pariter impetit.”

(The sixth place [nerve], in a new arrangement of enumeration, is the Trochlear nerve, which Fallopius claims to himself the authorship. It originates by small branches from the pons, a little above the inlet of the Fourth and Fifth, by the side of the region of the Natis and Testis [superior and inferior quadrigeminal bodies], and further, lying on the edge of the cerebellum, immediate to the roof of the second fold of the dura mater, is an oblique channel, near the eye, admitted in the course together with the first branch of the Fourth nerve, which is distributed

in the superior oblique mover [muscle] of the eye, which was once named Trochlear, both names received by the nerve) (Molinetti 1669).

FROM THE 19th CENTURY TO THE CURRENT UNDERSTANDING OF THE TROCHLEAR NERVE: THE ADVENT OF MICRONEUROSURGERY

In the 19th century, a new breakpoint in the anatomy of cranial nerves was achieved. The binomial anatomy-physiology was broken, and the attention was directed to microscopic anatomy, more specifically to intrinsic microscopic structures of the brain¹. The second and third periods, as devised by Porrás-Gallo et al.¹, begun after Soemmerring defined cranial nerve classification system and are still working through current days¹. It is worth noting that there is a significant time overlap between these periods and there was no new discovery in cranial nerve macroscopic anatomy in this interim.

A fourth milestone can be added to Porrás-Gallo et al.¹ categorization, namely the introduction of the microscope to the operating room (the microsurgical anatomy period). From the clinical point of view, it possibly marked the beginning of the fourth period of cranial nerve history. The interest in magnification has followed humans since ancient times²⁷. Even though there is considerable controversy regarding the inventor of the first microscope²⁷, it is credited to Carl Nylen, a Swedish otolaryngologist, the first use of a surgical microscope in humans in 1921²⁸. The surgical microscope has mainly interested ophthalmologists and otolaryngologists until 1957 when Theodore Kurze (1922–2002), became the first neurosurgeon to use the microscope in the operating room^{27,29}.

The late 1950s and 1960s were very prolific for microneurosurgery with the establishment of several microneurosurgical laboratories and the dissemination of microsurgical techniques²⁷. Besides Theodore Kurze, Robert Rand, Charles Drake, Peardon Donaghy, Lawrence Pool, and M. Gazi Yasargil were some of the leading pioneers who revolutionized microneurosurgery²⁷. The work of Albert L. Rhoton Jr provided the next step into cranial nerve history by highlighting specific microsurgical anatomy and emphasizing major clinical applications.

The microsurgical anatomy of the trochlear nerve is currently divided into five segments, namely brainstem, cisternal, tentorial, cavernous, and orbital^{6,30-32}. The brainstem segment begins in the trochlear nucleus and ends where efferent fibers merge under the inferior colliculi. After emerging from the dorsal midbrain, it continues anterolaterally around the surface of the brainstem and then continues anteriorly below the free

edge of the tentorium. The cisternal segment is particularly prone to injury since the nerve is not readily identifiable from the surgeons' perspective³³. Midline, paramedian and extreme lateral infratentorial-supracerebellar approaches, as well as the combined presigmoid subtemporal transtentorial approach, can all expose the cisternal segment of the trochlear nerve emphasizing the need for accurate anatomical knowledge to safely resect lesions in and around the tentorium³³.

The tentorial segment is a short and relatively fixed portion that comprises the nerve along the groove where it pierces the tentorium and a trigonal segment where the nerve is enveloped by an arachnoidal fold before reaching the tip of the anterior clinoid process³³. From a surgical standpoint, the tentorial segment of the trochlear nerve is particularly vulnerable to injury from a supratentorial perspective because the nerve is located commonly below the tentorium or might be displaced by an expanding lesion. After piercing the roof of the cavernous sinus, the trochlear nerve runs along the lateral wall of the cavernous sinus until the superior orbital fissure. Finally, the trochlear nerve enters the orbit as the most superior of all nerves, then emerges laterally to the lateral aspect of the annulus of Zinn and then crosses the levator palpebrae superior and superior rectus muscles to terminate generally at the medial aspect of the superior oblique muscle. Trochlear nerve anatomical preservation during orbital surgeries should consider nerve preparation and adequate identification before proceeding with the opening of the annular tendon³³.

CONCLUSIONS

Trochlear nerve history was marked by milestones over 250 years, from description (1520), proper naming (1669), and inclusion into cranial nerve classification systems (1778). In 2020, we celebrate five hundred years of trochlear nerve description by Achillini. Such history started much before through the observation of many great pioneers and continues. This nerve was the last cranial nerve to be described, potentially because it is a delicate nerve that becomes even more vulnerable due to its considerable long intracranial path and particular origin. Therefore, it is very likely that necropsy might have damaged it, which postponed its complete clarification. Later, at the beginning of the Italian Renaissance, the permission to use human specimens for the preparation associated with the great interest of refined anatomists favored its description. Now, trochlear nerve history reached the era of microsurgery, wherein accurate microsurgical knowledge is of utmost importance for the safe resection of lesions involving the posterior and middle fossas and the orbit.

REFERENCES

1. Porras-Gallo MI, Peña A, Viejo F, Hernández T, Puelles E, Echevarria D, Sanudo J. Overview of the History of the Cranial Nerves: From Galen to the 21st Century." *The Anatomical Record* (Hoboken, N.J.:2007). 2019;302:381-393.
2. Ballester LG. De la anatomía alejandrina al "Corpus Galineum" [From the Alexandrian Anatomy to the Corpus Galineum]. *Medicina e Historia* (2ª época) 1974;37:7-26.
3. Davis CD, Griessenhauer JC, Bosmia AN, Shane Tubbs R, Shoja MM. The naming of the cranial nerves: a historical review. *Clinical anatomy* (New York, N.Y.) 2014;27:14-19.
4. Smith ES. Galen's account of the cranial nerves and the autonomic nervous system. 1. *Clio medica* (Amsterdam, Netherlands) 1971;6:77-98.
5. Pearce JMS. Naming the Cranial Nerves: a historical note. *Advances in Clinical Neuroscience and Rehabilitation* 2017;16:12-13.
6. Ammirati M, Musumeci A, Bernardo A, Bricolo A. The microsurgical anatomy of the cisternal segment of the trochlear nerve, as seen through different neurosurgical operative windows. *Acta Neurochirurgica* (Wien) 2002;144:1323-1327.
7. Villain M, Segnarbieux F, Bonnel F, Aubry I, Arnaud B. The trochlear nerve: anatomy by microdissection. *Surgical and Radiological Anatomy*. 1993;15:169-173.
8. Achillini A, Achillini GF. *Annotationes anatomiae magni Alexandri Achillini Bononiensis* [Notes on the anatomy of the great Alexander Achilles of Bologna]. Per Hieronymum de Benedictis. 1520.
9. Matsen HS. Alessandro Achillini (1463-1512) and His Doctrine of 'Universals' and 'Transcendentals': A Study In Renaissance Ockhamism. Lewisburg: Bucknell University Press/London Assoc. 1974.
10. Soemmerring STh. *De basi encephali et originibus nervorum cranio egredientium libri quinque* [The base of the brain and the origin of the nerves going out of the skull]. Vandenhoek Widow: Göttingen. 1778.
11. Lind RL. *Studies in pre-Vesalian anatomy. Biography, translations, documents*. Philadelphia: American Philosophical Society. 1976.
12. Shaw JP. A history of the enumeration of the cranial nerves by European and British anatomists from the time of Galen to 1895, with comments on nomenclature. *Clinical Anatomy*. 1992;5:466-484.
13. Vesalius A. *Andreae Vesalii Bruxellensis, scholae medicorum Patavinae professoris, de humani corporis fabrica libri septem*. Basileae: ex officina Ioannis Oporini. 1543
14. Realdo Colombo M. *De re Anatomica Libri XV*. Nicolò Bevilacqua: Venice. 1559.
15. Rocca J. Galen on the brain: anatomical knowledge and physiological speculation in the second century AD. *Studies in ancient medicine*. 2003;26:149.
16. du Laurens. *De singulis oculi partibus cap XVI in Opera anatomica in quinque libros divisa*, Lugduni: sumptibus Ioannis Baptistae Buyssoni, p. 701-702. 1593.

17. De Laey JJ. The eye of Vesalius. *Acta ophthalmologica* 2011;89(3):293–300. <https://doi.org/10.1111/j.1755-3768.2009.01679.x>
18. Flamm ES. Historical observations on the cranial nerves. *Journal of Neurosurgery* 1967;27:285-297.
19. Hierons R, Meyer A. 1962. Some priority questions arising from Thomas Willis' work on the brain. *Proceedings of the Royal Society of Medicine* 1962;55:287-292.
20. "Faloppio, Gabriele ." Complete Dictionary of Scientific Biography. . Retrieved April 29, 2022 from Encyclopedia.com: <https://www.encyclopedia.com/science/dictionaries-thesauruses-pictures-and-press-releases/faloppio-gabriele>
21. "Eustachi, Bartolomeo ." Complete Dictionary of Scientific Biography. Retrieved April 25, 2022 from Encyclopedia.com: <https://www.encyclopedia.com/science/dictionaries-thesauruses-pictures-and-press-releases/eustachi-bartolomeo>
22. Eustachi, Bartolomeo. TABULA XVIII Delineat nervorum omnium originem a spinali medulla tam intra, quam extra cranium. Available from: https://www.univ-brest.fr/digitalAssets/72/72005_planche-XVIII-traduction-d-finitive.pdf
23. Willis T. *Cerebri anatome: cui accessit nervorum descriptio et usus*. Londini: typ. J. Flesher, imp. J. Martyn & J. Allestry. 1664.
24. Bartholin C. *Institutiones Anatomicae. Nicolai Dunckeri: Goslariae*. 1632.
25. Molinetti A. *Dissertationes anatomicae et pathologicae De sensibus et eorum organis* [Anatomical and pathological dissertations on the senses and their organs. From the typography of Matthew Bolzetta of Cadorinis]. Ex typographia Matthaei Bolzetta de Cadorinis. 1669.
26. Pearce JMS. Samuel Thomas Soemmerring (1755-1830): The Naming of Cranial Nerves. *European Neurology* 2017;77:303-306.
27. Kriss TC, Kriss VM. History of the operating microscope: from magnifying glass to microneurosurgery. *Neurosurgery* 1998;42:899-908.
28. Nylen CO. The otomicroscope and microsurgery. *Acta Otolaryngologica* 1972;73:453-454.
29. Donaghy RMP. The history of microsurgery in neurosurgery. *Clinical Neurosurgery* 1979;26:619- 625.
30. Bisaria KK. Cavernous portion of the trochlear nerve with special reference to its site of entrance. *Journal of Anatomy* 1988;159:29–35.
31. Gupta T, Gupta SK, Sahni D. Anatomy of the tentorial segment of the trochlear nerve in reference to its preservation during surgery for skull base lesions. *Surgical and Radiological Anatomy* 2014;36:967–971.
32. Zhang Y, Liu H, Liu EZ, Lin YN, Zhao SG, Jing GH. Microsurgical anatomy of the ocular motor nerves. *Surgical and Radiological Anatomy* 2010;32:623–628.
33. Joo W, Rhoton Jr AL. Microsurgical anatomy of the trochlear nerve. *Clinical Anatomy (New York, N.Y.)* 2015;28:857-864.