

Beethoven's illnesses and a craniovertebral junction variant?

As doenças de Beethoven e variante da junção craniovertebral?

M. da Mota Gomes¹

ABSTRACT

Ludwig van Beethoven, the great composer, born 250 years ago, had several health problems and a progressive hearing loss. Gastrointestinal symptoms prevailed among his physical complaints, but there were also frequent headaches, eye pain, and polyarthralgia. Likewise, there are many reports about his alcohol intake and frequent walks. There were also peculiar behavioral and awkward physical aspects of the famous composer. All may take part as a determinant for the communicative aspects of his music. Spite Beethoven's corporal structure could be considered just a developmental variant, it can also be congenitally related to many bone-nervous abnormalities such as craniovertebral junction malformation with interference in the Genius' health. In reality, it is almost impossible to cover Beethoven's entire health problem with just one underlying disease. Most likely, he had comorbidities, one of which, although not fatal, was that related to abnormalities in the development of the skull and cervical spine worsened by a baseline autoimmune disorders that injured joints, and maybe even the VIII cranial nerve and inner ear.

Keywords- Deafness, Craniovertebral junction malformation, radiology, history of medicine

RESUMO

Ludwig van Beethoven, o grande compositor, nascido há 250 anos, teve vários problemas de saúde e uma perda auditiva progressiva. Os sintomas gastrointestinais prevaleceram entre suas queixas físicas, mas também houve frequentes episódios de cefaleia, dores nos olhos e poliartralgia. Da mesma forma, há muitos relatos sobre sua ingestão de álcool e caminhadas frequentes. Havia também aspectos físicos peculiares e estranhos do famoso compositor. Todos podem tomar parte como um determinante para os aspectos comunicativos de sua música. Apesar da estrutura corporal de Beethoven poder ser considerada apenas uma variante de desenvolvimento, pode também estar relacionada a algumas anormalidades ósseo-neural, tais como a malformação da junção craniovertebral com interferência na saúde do Gênio. Na realidade, é quase impossível cobrir todo o problema de saúde de Beethoven com apenas uma doença subjacente. Muito provavelmente, ele tinha comorbidades, uma das quais, embora não fatal, era aquela relacionada a anormalidades no desenvolvimento do crânio e da coluna cervical agravadas por uma desordem auto-imune de base que lesionava as articulações, e talvez até o VIII nervo craniano e o ouvido interno.

Palavras-chave - Surdez, malformação da junção craniovertebral, radiologia, história da medicina

¹- Laboratory of History of Psychiatry, Neurology, and Mental Health, Institute of Psychiatry. Institute of Neurology. Federal University of Rio de Janeiro, Rio de Janeiro, Brazil Orcid: <https://orcid.org/0000-0001-8889-2573>

INTRODUCTION

This paper is a tribute to Ludwig van Beethoven (baptism December 17, 1770, Bonn, Kurköln -† March 26, 1827, Vienna), a German composer and pianist, born 250 years ago.

At the beginning of his musical career, Beethoven made his name as a piano virtuoso. After moving from Bonn to Vienna, his talent soon took him to the highest social circles. As his hearing deficiency had deteriorated, Beethoven concentrated more and more on composition, and he ended his career as a pianist, and later as a conductor. At the same time, this great composer had many illnesses throughout his life, besides his habit of walking and drink wine.

This article is an overview of the genius' ailment^{1,4,12,14,15}, but mainly about his peculiar body conformation and head, that was extraordinarily large based on contemporary accounts on 'The young Beethoven'⁵. It is questioned if this particular body shape would be related to his deafness, which led to several hypotheses, but any related to developmental osseous variant.

OVERVIEW OF BEETHOVEN'S DISEASES

Beethoven had deafness since the age of 28, firstly from the left ear, and the early symptoms included tinnitus and high-tone hearing loss, initially intermittent, but after one year, they became persistent⁵. At the age of 44, he became deaf⁷.

He reported the most crucial health complaints (1792), as Beethoven says, '... my hearing has grown steadily worse for three years for which my bowels, which you know were always wretched and have been getting worse, since I am always troubled with a dysentery, in addition to unusual weakness, are said to be responsible...'¹⁵. Besides, Beethoven's complaints also included recurrent headaches, painful eye inflammation, nose bleeds, and polyarthralgia^{5,7}.

Regarding Beethoven's last few months of life, there is a critical turn point in his health status. On his journey to Vienna, in wet and cold weather, in early December, Beethoven contracted pneumonia. Nevertheless, there were already signs of anasarca since autumn. After four paracentesis and ineffective attempts at treatment for the ascites and primary disease, Beethoven died at the end of March. His last doctor was Andreas Ignaz Wawruch, among many other outstanding physicians who attend him^{5,7,11}.

The necropsy performed in Beethoven's house the day after death by the best-renowned anatomist of the day, Johann Wagner, and the later famous Karl

Rokitansky^{5,7}. Beethoven's remains were exhumed twice when occurred: the reconstruction of the skull (1868); his remains were transferred to another cemetery (1888)^{4,7,11}

At his necropsy, there were anasarca and involvement of the liver (atrophic, macronodular), spleen (enlarged), pancreas (enlarged and hardened), kidneys (pale with calcifications) and intestines (distended and with abundant gases)⁷. Regarding the nervous system, the report is⁴:

'Nervi faciei' were noticeably thickened while the acoustic ones appeared shrunk 'et sine medulla'; the respective one's caliber arteries like a goose quill, of cartilage consistency. The acoustic nerve very subtle left took origins from three very tenuous roots of gray color, the right one from a more consistent root than whitish color; the surface layer surrounding the fourth ventricle was of increased consistency and more vascularized than the nerves that originated from it. The brain was softer and more edematous, the convolutions appeared deeper numerous than normal. The cranial vault was strongly and uniformly compact of the about half an inch (1.25 cm) thick.¹⁴

To all Beethoven's clinical symptomatology, many diagnoses were raised, such as Paget's disease of the bone (PDB), primary hyperparathyroidism, hemochromatosis⁴.

Regarding PDB diagnosis, there are many points against it, as a uniform thickening of the skull, reported visually by many already in his youth¹².

Anyhow, Beethoven may have an underlying multisystemic disease complicated by . the use of alcohol and possibly other drugs to relieve the symptoms. Indeed, these together may drive to the clinical differential diagnosis of a central disease related to an autoimmune disease (Inflammatory bowel disease, Rheumatoid arthritis, Systemic Lupus Erythematosus) or chronic granulomatous disease (Tuberculosis, Syphilis, Sarcoidosis), besides comorbidities, such as gastrointestinal hepatic infection diseases (typhus, viral hepatitis and Whipple's Disease)^{4,6,7}.

This complex symptomatic diversity, including Beethoven's headache and hearing loss, may also have had an associated problem, such as a variant of bone development, to be demonstrated in the next section.

Regarding the suspected etiologies to justify the main physical symptoms of Genius, there are autoimmune, and also toxic ones. Beethoven's hair contained a high concentration of lead, probably linked to the ingestion of drugs and the wine that contained them. Coincidentally, it was demonstrated in the "history" of hair, possible to register and examine by its slow growth, that there was a peak of lead coincidentally after the treatment of pneumonia and the four paracenteses¹¹. In addition, there was also an occasional increase in the concentration of lead in the hair, probably related to wine consumption by

Beethoven, since some wine producers corrected the product by adding lead monoxide or lead sugar¹¹.

Another toxic health outcome may have antecedent the Beethoven's use of salicylate precursors for his headaches and rheumatism that would induce side-effects as those for the kidneys⁵.

A further less explored issue concerns probable cerebral cortical atrophy. As it is known, chronic alcoholism is usually related to it, but at least in part, it can reverse when abstinence is maintained.

Regarding the possible causes of Beethoven's deafness, they were included recurrent otitis media leading to middle-ear deafness, nerve deafness, otosclerosis, and others, among them, PDB^{5,7,9}. This last osseous disease repetitively was suggested as the cause of Beethoven's deafness, and now, it has added a new possibility among this bone category.

However, all the medical etiological hypotheses raised regarding Genius' health have assets and flaws as approached in many reviews about Beethoven's health status^{4,5,7} (Figure 1).

impression regarding head morphology, as well the body segmental composition. This author mentions that Beethoven was short, no more than 5 feet and 5 inches tall, and a somatotype broad in build. Also, *his head was extraordinarily large* with a broad forehead, just as his nose was. The chin was divided unevenly by a deep slit, as for his hands, they were wide and with short fingers.

Additional information regarding Beethoven's body outlook is presented by some pictures, more accurately by those regarding his life mask (Figure 2).

As shown in figure 2, Beethoven and his father have peculiar head shape suggestive of developmental diversity. However, both individuals had also a suggestive short neck that conjointly characterizes a craniovertebral junction (CVJ) variant.

Firstly, regarding CVJ anomalies denomination, there were in the literature some confusion between basilar invagination and platybasia; this last one can be only an anthropology term. The first concerns the inward and

Main necropsy findings

- ✓ enlarged skull
- ✓ enlarged facial nerve
- ✓ auditory nerve atrophy
- ✓ brain "exaggerated folds"
- ✓ cirrhosis
- ✓ ascites
- ✓ enlarged spleen
- ✓ hard pancreas
- ✓ calcium nephrolitiasis

A lifelong symptom

- ✓ deafness



Revisiting Beethoven's disabilities physical spectrum: from toxic and infectious to autoimmune cause?

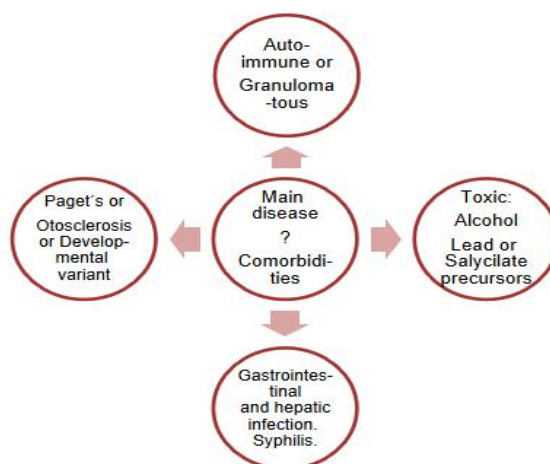


Figure 1. Beethoven, energetic walker and nature lover, amid his illnesses. Standing Beethoven Monument (1845), by Jacob Daniel Burgschmiet, after a project by Ernst Julius Haehnel that captures the conductor's work while walking at Bonn's Münsterplatz, the birthplace of Beethoven. Figure on public domain.

BEETHOVEN'S SKELETAL PHENOTYPE

A less studied Beethoven's side of ailments are those related to his body conformation and ancestry. There are many reports about Beethoven's body outlook.

Fischer, apud Schieder¹², describes Beethoven: 'Short, squat, broad in the shoulders, *short of the neck, thick head*, round nose, black-brown complexion; something always happened bent over. He was called in the house, formerly as a boy, the Spangol = Spagnuolo, because of the dark complexion'. Squire¹⁴ reinforces this

upward migration of the cervical spine through the foramen magnum. Regarding platybasia, it is characterized by excessive flattening of the skull base and obtuseness of the angle between the anterior skull base and the clivus^{10,13}.

Concerning basilar invagination, it can occur in a variety of congenital disorders or acquired diseases. Among the congenital disorders, they may occur, i.e., Chiari malformation, syringomyelia, Klippel-Feil syndrome. Regarding acquired diseases, it may take place together

with rheumatoid arthritis, PDB, Osteogenesis imperfecta (also associated with hearing loss from otosclerosis)^{3,5}.

Several signs and symptoms of CVJ anomalies may happen as motor myelopathy, sensory abnormalities, brain stem dysfunction, vascular compromise, and lower cranial nerve dysfunction, including decreased hearing¹³. Although most of the patients' symptoms require neurological care, many of them have cranial nerve deficits (for example, vertigo, dysphagia, facial paralysis, decreased hearing, atrophy of the tongue) result, which can be seen at otorhinolaryngological clinics¹³. In Klippel Feil syndrome, a fusion of the cervical vertebrae, all types

symptomatology. Beethoven was able to take long and vigorous walks in the Vienna surroundings even many months before he passed away⁹. Besides, he did not have vestibular symptoms⁷.

These clinical manifestations of CVJ anomalies would be derived by altered CSF dynamics, pressure or traction on the structures, and maybe dysfunctional vertebrobasilar blood supply. Besides, some bone assimilation malformation and platybasia have also been listed⁵. Likewise, in the 66 cases reported by Caetano de Barros et al. ³, the analysis of the main complains at the first medical consultation includes among the most common one: headache (53 %), dizziness, and dysphagia

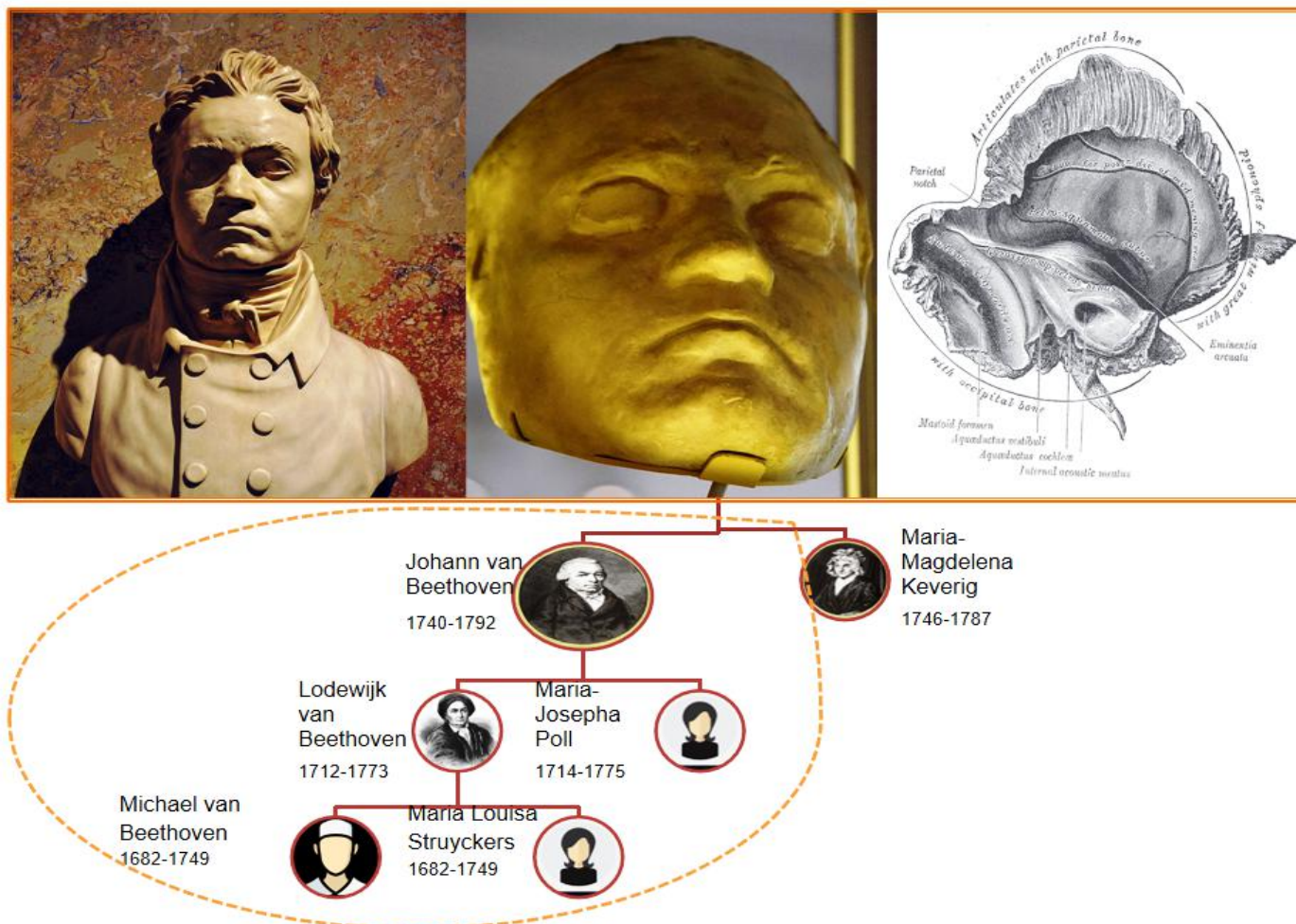


Figure 2. Beethoven's lineage, and craniocervical junction outlook. At the top: Ludwig van Beethoven (Vienna, Kunsthistorisches Museum, collection of old musical instruments (Neue Burg). Sculptor: Franz Klein, Vienna). This bust was first taking as Beethoven's Life mask, c. 1812 (The Wellcome Collection, London). These sculptures show a homogenous protuberant forehead and massive jaw and chin. The pyramid-shaped petrous part of the temporal bone is among the most basal elements of the skull, and near the center of its posterior surface, it exists the internal auditory meatus (Gray's Anatomy, Plate 138 (1918)). At the bottom: Beethoven's father picture depicts a man of Flemish origin with a short neck and large head. Figures on public domain.

of hearing problems have been described, and it is a well known associated feature, but the bilateral sensorineural loss is most common⁸. In these patients, several otological findings were observed, from the external ear to severe cochlea development abnormalities⁸. It should be remembered that Beethoven had, in addition to deafness, also headache, which could be due to CVJ anomalies. However, despite the possible Beethoven's CVJ anomalies, he did not have many of the mentioned related

were cited by more than one-third (37 %), pains in the nape pains in the nape of the neck (28%), other less commonly reported include dizziness (21 %), but less frequently, diminished hearing (7%).

The initial report about basilar invagination and a small posterior fossa is delineated in cretins from the Alps by Ackermann, in 1790. Later (1856), Anders Adolph Retzius and Frederik Theodor Berg, both accomplished anthropologists, according to Spillane, apud Pearce¹⁰,

were also one of the first to refer to basilar invagination. Regarding Retzius, he realized that in Sweden, the Germans had narrow skulls, while the Lapps had enlarged ones; he formulated these shapes mathematically by their cephalic width/length index. However, his arrangement did not corroborate specific 'race' patterns, since the different forms are present in each group, as Rudolf Virchow also realized^{10,2}.

Besides, Rokitansky, one of Beethoven's necropsist, described the accompanying occipitalisation of the atlas (1844). Concerning Virchow, he created the term 'platybasia' to depict an abnormal flattening of the skull base, which he considered linked to abnormal bone development (1856)¹⁰. However, in 1875, Virchow declared it impossible to establish exact craniological types for Germans, Celts, Slavs, Finns, or Italians, besides, as all were a product of a mixture of smaller elements. In 1876, Wirchow launched his 'Contributions to the Physical Anthropology of the Germans,' when he was able to show that the old German cranial type, as represented by the Frisians, were chamaeprosopic (short and broad faces) and mesocephalic, rather than dolichocephalic². Indeed, Virchow noted the physical characteristics of the Germans, mainly the Frisians, in whom he revealed that basilar invagination was occasionally seen with platybasia¹⁰.

Besides, Boogaard (1865)¹⁰ comprehensively inspected skull platybasia by using angular skull measurements. However, the earliest radiologically report about basilar invagination was made by Schüller (1911), and later several radiologists established landmarks to make this diagnosis. In this way, the possibility of an accurate preoperative diagnosis of basilar invagination was established by Chamberlain et al. (1939), aside from variants measurements such as those by McGregor's line, as sagittal lines¹³. Regarding coronal lines, exist e. g., Fischgold's digastric line. All were establishing the upper ward limits of the odontoid process. Concerning platybasia, there are radiological measurements, such as Welcher basal angle¹³.

About Beethoven's Flemish paternal ancestry, his family was native to Flanders, Antwerp, where there were also the Frisians, originating from a German tribe^{10,16}. Precisely, these people were considered more prone to platybasia among the German people diversity studied by Virchow¹⁰. This information is relevant to reinforce the probability of Beethoven's CVJ anomalies.

Indeed, clusters of this cranial phenotype are recognized in other places, but as Goel⁵ says, the ground for this geographical agglomeration is theoretical.

Regarding Brazil, the northeastern region has a high rate of individuals with this CVJ diversity. By coincidence, Caetano de Barros et al. ³ hypothetically suggest that may occur some connexion between endemic spots, as this Brazilian region had been occupied for 34 years by the Dutch in the 17th century. In India, Goel⁵ even says that CVJ anomalies are more commonly established in this

subcontinent than anyplace else, but more often recognized in some of its regions.

Consequently, the classic severe findings of basilar invagination or Chiari malformation probably did not affect Beethoven during his lifetime. However, a secondary anomaly of CVJ, such as a result of PBD, does not seem to be the best hypothesis to justify cephalic complaints as his enlarged head was homogeneous, already perceived early in his life, and in line with his family propensity.

More reasonably, Beethoven's cephalic complaints, hearing loss and headache, would have multiple mechanisms. These would include induced otosclerosis and auditory nerve deafness caused by bone abnormalities in the petrous part of the temporal bone, maybe lesions in the lower cranial nerves, and cervical radiculopathy, all in conjunction with CVJ abnormalities, aggravated by an underlying systemic autoimmune disease.

FUNDING STATEMENT: The author did not receive funding for this work.

DECLARATION OF AUTHOR COMPETING INTERESTS: The author declares no competing interests.

REFERENCES

1. Beethoven: The Man and the Artist, as Revealed in His Own Words. Friedrich Kerst and Henry Edward Krehbiel. Project Gutenberg eBook. February 9, 2009 eBook #3528.
2. Boak AER. Rudolf Virchow-Anthropologist and Archeologist. The Scientific Monthly 1921;13(1):40-5.
3. Caetano de Barros M, Farias W, Ataíde L, Lins S. Basilar impression and Arnold-Chiari malformation. A study of 66 cases. J Neurol Neurosurg Psychiatry. 1968;31(6):596-605.
4. Fellin R, Richert J. Sulla malattia di L. van Beethoven. Giornale Italiano dell'Arteriosclerosi 2019; 10 (4): 63-75.
5. Goel A. Basilar invagination, Chiari malformation, syringomyelia: a review. Neurol India. 2009;57(3):235-46.
6. Hui AC, Wong SM. Deafness and liver disease in a 57-year-old man: a medical history of Beethoven. Hong Kong Med J 2000;6(4):433-8.
7. Kubba AK, Young M. Ludwig van Beethoven: a medical biography. Lancet. 1996;347(8995):167-1670.
8. McGaughan JM, Kuna P, Das V. Audiological abnormalities in the Klippel-Feil syndrome. Arch Dis Child 1998;79(4) 352-3.
9. Oiseth SJ. Beethoven's autopsy revisited: A pathologist sounds a final note. J Med Biogr 2017;25(3):139-47.
10. Pearce JM. Platybasia and basilar invagination. Eur Neurol 2007;58(1):62-4.
11. Reiter CH. The Causes of Beethoven's death and His Locks of Hair. A Forensic-Toxicological Investigation. The Beethoven Journal 2007;22-1:2-5.
12. Schiedermaier L. Der junge Beethoven. Reprint of the Leipzig edition, 1925 by Herstellung: Strauss & Cramer, 1978, 167-8.
13. Smoker, Wendy R. K.. 'Craniovertebral junction: normal anatomy, craniometry, and congenital anomalies.' Radiographics : a review publication of the Radiological Society of North America, Inc 14 2 (1994): 255-77 .
14. Squire WB. Beethoven's Appearance. Music & Letters 1927;8(2):122-5.
15. Sullivan JWN. Beethoven: His Spiritual Development. New York: Alfred-A-Knoff, 1936, 103-4.
16. The Family of Beethoven. The Musical Times and Singing Class Circular 1877; 18(413), 327-9. doi:10.2307/3355497